

DERMATOFIBROSARCOMA PROTUBERANS, A CHALLENGING ENTITY – CASE REPORT AND BRIEF LITERATURE REVIEW

**A.C. TINCA^{1,2} B.A. LAZAR² E.S. NEGOVAN³
O.S. COTOI^{1,2}**

Abstract: *Dermatofibrosarcoma protuberans (DFSP) is a rare, locally aggressive soft tissue tumour of mesenchymal origin, commonly arising in the dermis and extending into deeper tissues. This article presents a case of a 52-year-old male with recurrent DFSP affecting the posterior neck region. Initial surgical excision in 2016 revealed a spindle-cell tumour with storiform patterns and a low mitotic index, while recurrence in 2022 exhibited a multinodular, infiltrative mass with increased cellular atypia and a high mitotic rate. Immunohistochemistry confirmed diffuse CD34 positivity in both instances. Complete surgical excision, including re-excision for margin involvement, achieved tumour-free status. The case highlights the importance of histological evaluation, surgical approach and follow-up in these cases. Long-term monitoring remains essential due to DFSP's high recurrence potential.*

Key words: *dermatofibrosarcoma protuberans, soft tissue, immunohistochemistry.*

. Introduction

Dermatofibrosarcoma protuberans (DFSP) is a rare entity but at the same time one of the most common soft tissue tumors encountered. This tumor has mesenchymal origin and arises from fibroblasts, involves the dermis and extends into deeper layers of the skin [1,2].

DFSP usually presents slow growth and lack of symptoms, being mostly a painless mass that arises anywhere on the body: head and neck region, trunk or the extremities. Older lesions present a multinodular growth and can reach big dimensions. Some tumors exhibit rapid growth, characteristics mostly encountered in the fibrosarcomatous differentiation of the entity [1], [3].

¹ "George Emil Palade" University of Medicine, Pharmacy, Science and technology Targu Mures

² Pathology Department of Clinical County Hospital Mures

³ Plastic Surgery Department of Clinical County Hospital Mures

From an etiology perspective, DFSP is usually sporadic, yet some cases can be multicentric and present an association with genetic disorders. Any age can be involved, and the tumor was diagnosed even in infants (congenital DFSP).

DFSP is most seen in the reticular dermis and presents with infiltrative, ill-defined borders, with extensions into subcutis. The histological particularities of the tumor reveal in the conventional form a proliferation of spindle cells which present uniform shape and are distributed in fascicles, with evident storiform pattern. The extension into the subcutis and involvement of the adipose tissue has given the tumor a particular phenomenon known as “honeycomb”. In the suprajacent epidermis, in contrast to its benign counterpart (dermatofibroma), the epithelium does not manifest any characteristic changes. DFSP presents multiple subtypes (pigmented, myoid, giant cell fibroblastoma- most common in children, granular cell, plaque like, etc.). From an immunohistochemistry point of view, the tumor presents intense and diffuse positivity for marker CD34 [4-6].

Clinically, DFSP presents with high risk of recurrence. If the tumor presents fibrosarcomatous transformation, the risk of metastasis is also considered, therefore complete excision and follow-up of the patients are mandatory [7].

2. Case report

We report the case of a 52-year-old male patient with no significant medical history, presenting the evolution of dermatofibrosarcoma protuberans (DFSP).

In 2016, the patient sought treatment at the Surgery Department of Mures Clinical

County Hospital for a painful ulceration located on the posterior side of the neck.

In 2022, the patient returned with a giant, multinodular cutaneous mass affecting the retroauricular and posterior neck region, at which point he was admitted to the Plastic Surgery Department of the same hospital.

The tumors were surgically exercised at the mentioned times, and the tissue samples were sent to the Pathology Department for examination.

In 2016, the 44-year-old patient (at that time) presented to the Surgery Department with a painful ulceration located on the posterior side of the neck.

On gross examination, we identified a cutaneous sample of 21x10 cm, with multiple ulcerations on the surface. On the cut section we observed sub adjacent and in the subcutaneous tissue an ill-defined tumor, white in color, measuring 13x6 cm, without other particularities.

The microscopic examination on the usual Hematoxylin-eosin (HE) stain revealed a tumor proliferation located in the mid-dermis and hypodermis. The tumor was hypercellular and consisted of fascicles of spindle cells with storiform arrangement. The tumor cells were elongated, presented reduced cytoplasm and monomorphic, oval or spindle nuclei. “Honeycomb” pattern was observed in the deep areas of the tumor. The mitotic index was low (5 mitoses/mm²) and the surgical resection margins were negative (figure 1).

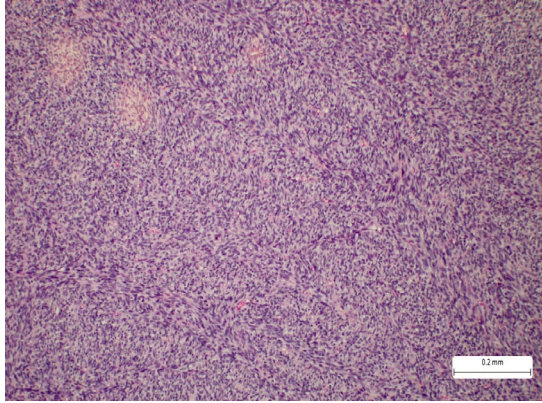


Fig. 1. Hypercellular tumoral proliferation with storiform pattern, composed of spindle cells with elongated nuclei. (HE)

The immunohistochemistry (IHC) profile of the tumoral cells presented positive reaction for CD34 and vimentin and negative reactions for SMA, desmin, S100, CD117 and SOX10 (figure 2).

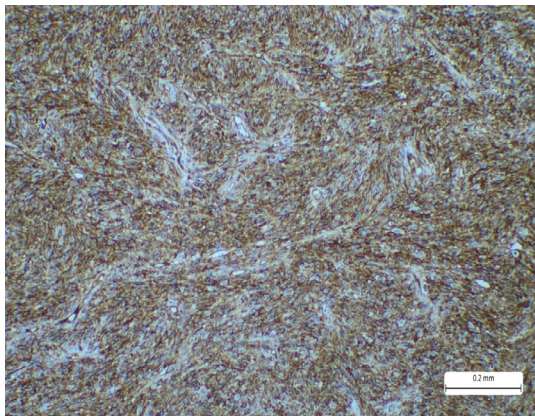


Fig. 2. Immunohistochemistry reaction with CD34 showing intense and diffuse positivity on the tumour cells (marker of the cell membrane)

Based on histology and IHC profile, diagnosis of dermatofibrosarcoma protuberans was established.

Follow-up was made and the patient presented full recovery with no recurrence at six months.

In 2022, the 50-year-old patient (at that time) returns to the hospital and gets committed to the Plastic Surgery Department for a giant nodular mass involving the posterior side of the neck extended to retroauricular area, which presented rapid growth in the past months.

On gross examination, we identified tumor proliferation with multinodular aspect, with total dimensions of 15x10 cm (figure 3).

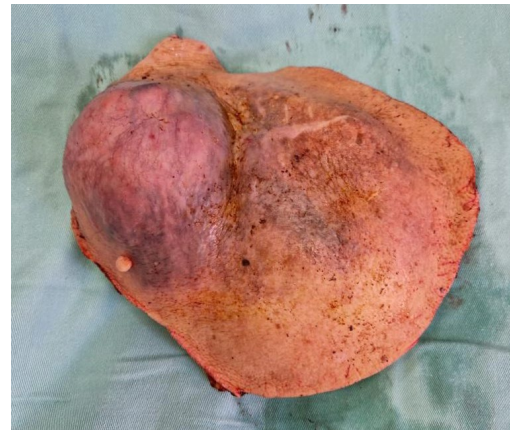

Fig. 3. Gross examination of the tumor recurrence showing a multinodular growth, reddish in coloration, with irregular borders

The histological examination of the tumor on H&E staining revealed a proliferation with characteristics similar to those previously described. Thus, we observed fascicles of spindle cells involving both the dermis and the hypodermis. The tumor spindle cells exhibited a predominantly monomorphic appearance, shown by elongated or oval nuclei along with eosinophilic or pale cytoplasm. Additionally, focal areas of necrosis and a high mitotic index (25/mm²) were identified. The tumor infiltrated the deep surgical resection margin (figure 4, 5, 6).

IHC analysis revealed strong and diffuse positivity for markers CD34 and vimentin. (figure 7)

Considering the patient's history, clinical presentation, histological findings, and IHC profile, the diagnosis of dermatofibrosarcoma protuberans was made.

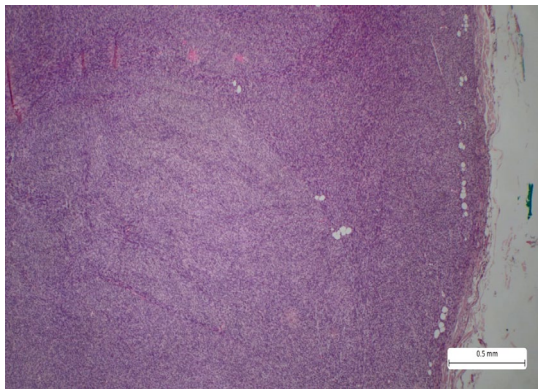


Fig. 4. Tumour proliferation with solid architecture, fascicles and storiform pattern, composed of elongated spindle cells. Deep surgical resection margins are infiltrated. (HE)

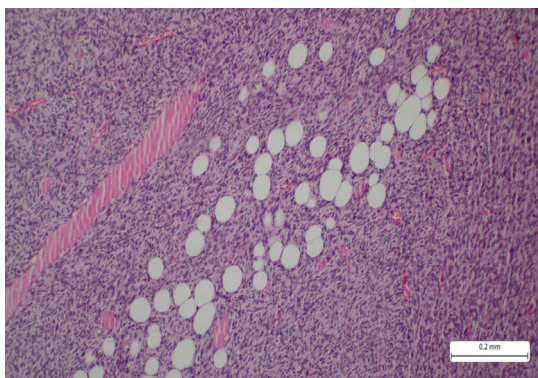


Fig. 5. "Honeycomb pattern" showing entrapment of the adipose tissue. (HE)

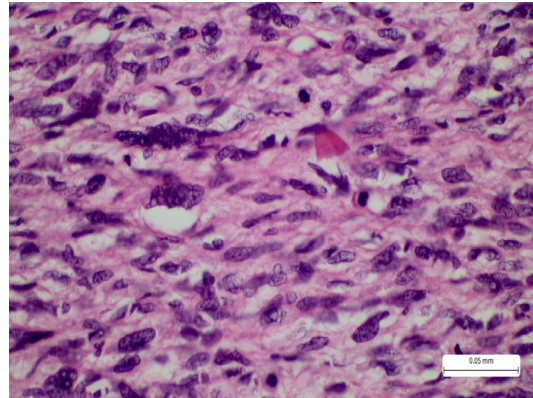


Fig. 6. Areas of high atypia with increased mitotic count, seen by marked pleomorphism, enlarged and hyperchromatic nuclei. (HE)

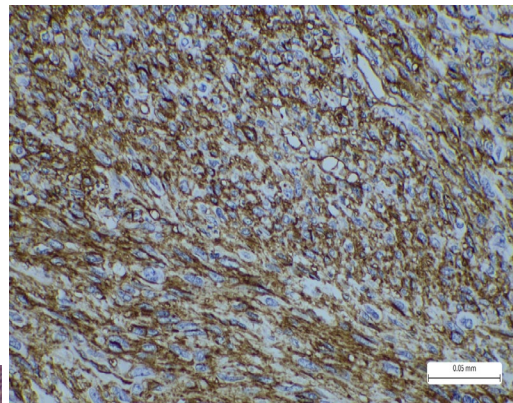


Fig. 7. Immunohistochemistry reaction with membranar marker CD34 shows intense and diffuse positivity

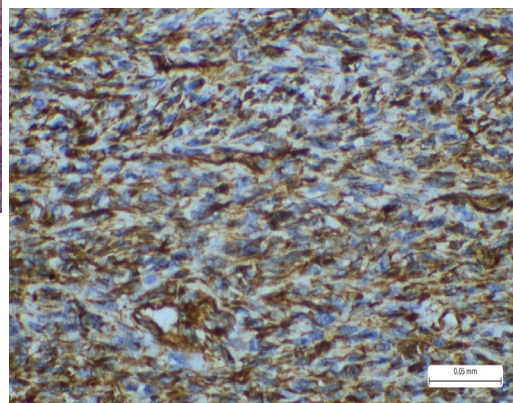


Fig. 8. Immunohistochemistry reaction with cytoplasmic marker vimentin shows intense and diffuse positivity

According to World Health Organization (WHO) and American Joint Committee on Cancers (AJCC) protocols, staging is made only in fibrosarcomatous differentiation, and thus it was not established for our case.

Due to margin infiltration, a surgical re-excision was performed. Complete analysis of the sample revealed a well-defined fibrous scar with abundant collagen fibers and hemorrhagic areas. Residual tumor cells were not seen. After two years, the patient remains free of recurrence or any new tumors. The patient remains under continuous follow-up.

3. Discussion

Dermatofibrosarcoma protuberans is a malignant tumor arising from the fibroblasts or histiocytes and is located commonly in the dermis. The anatomical areas affected are diverse, therefore the neoplasm develops on the trunk, limbs and head and neck area as well [8].

The age interval that can be involved is very large; patients of all ages can be affected. The tumor has been described most often in young individuals, and some cases were also seen in children (pediatric or congenital DFSP). The diagnosis in children is often delayed because the tumor has very slow growth and in early stages can be confused with other conditions. Older individuals can also be affected, but more rarely [9].

Our case revealed DFSP in a 44-year-old patient with location on the posterior side of the neck. Surgical resection was performed. Six years after this diagnosis, the patient returned to the hospital with a multinodular giant mass located in the posterior neck, extending to the retroauricular area. The surgical resection margin was infiltrated by the tumor, and re-excision was performed.

Usually, most DFSP involve the trunk, followed by the limbs and the head and neck region. If the tumor is recurrent, it can affect the fascia, muscles and even infiltrate the bone. Dermatofibrosarcoma located on the scalp presents with high risk of recurrence due to challenges in achieving complete resection. The tumor can develop again even if negative margins are achieved. Patients that have large lesions or who present frequent relapses require a multidisciplinary team that can provide them with additional treatment, such as radiotherapy or monoclonal antibodies (Imatinib) [10,11].

Initially, the patient presented a tumor located in the dermis which extended in the hypodermis, without involvement of the deeper tissues. The recurrence however was a highly infiltrative tumor that grew larger and infiltrated the deep surgical margin.

Histology of DFSP reveals a fibrous tumor with storiform pattern, located in the dermis and subcutaneous tissue. The tumor is composed of spindle, elongated cells with uniform, unique nuclei. Mitoses are not numerous. One of the most important aspects of the lesion is the presence of the honeycomb pattern, where single or groups of a few adipocytes are entrapped within the tumor tissue [1], [12,13]. Our case presented in the primary tumor and later in the recurrence, characteristics that are specific for DFSP. The tumor cells in both situations were distributed in fascicles with storiform pattern. The first tumor presented a dimension of maximum 8 cm and clinically was associated with pain. The recurrence showed a multinodular giant mass of cm which was extended in the posterior side to the neck up to the retroauricular area, also associated with pain. Histology showed similar aspects with the first tumor, but this time the deep resection

margin was infiltrated. The honeycomb pattern was identified in both cases, and the number of mitoses varied, with less than 5/mm² in the first lesion and approximately 20/mm² in the second.

The differential diagnosis for DFSP is important, especially in the cases with fibrosarcomatous differentiation. One of the tumors that need to be taken into consideration, especially on superficial biopsies, is dermatofibroma, especially cellular type. This tumor is benign and presents various proportions of spindle cells, collagen fibers and histiocytes. Dermatofibroma (DF) is known as fibrous histiocytoma, and it is one of the most common soft tissue tumors that can affect people of any ages. Clinically, dermatofibromas are asymptomatic or present with various symptoms, such as pain (similar to DFSP) or itching. Usually, the tumor presents under the form of papules or nodules, which are reddish or brown in appearance. There are multiple histological subtypes of this entity, and some of them can cause important differential diagnosis challenges. Dermatofibroma can present with atypical cells, sometimes multinucleated, sometimes with palisading areas and hypercellularity, and mitoses are commonly seen. The tumor does not usually infiltrate the subcutaneous tissue, and the honeycomb pattern is absent. In addition, conventional DF presents with characteristic epidermal hyperplasia with abundant melanin pigment in the basal layer, particularly important for shave biopsies and superficial samples. [14-16]

Immunohistochemistry can be a helpful tool for differentiating these two entities using CD34 immunostaining and sometimes factor XIIIa. CD34 shows diffuse positivity in DFSP, while the stroma of DF is negative, only expressed in the periphery of the lesion. Certain studies evaluated the

expression of D2-40 in distinguishing these tumors. The markers can be positive in a significant number of DFSP, but additional studies are required [17].

Another differential diagnosis is solitary fibrous tumor (SFT), a mesenchymal, soft tissue tumor that can present high histological variability. In the past, SFT was reported in the thorax, lung and pleura, but later they were acknowledged and diagnosed as tumors that can involve any area of the body. SFT usually presents with slow growth and lack of symptoms (this also depends on the organs that can be affected). On gross examination, these entities are multinodular, circumscribed, firm and white in color. On microscopic examination, they are composed of spindle cells, collagen fibers with fasciculate, storiform patterns. Sometimes, myxoid changes can be observed, but the conventional form presents a fibrous stroma. Lipomatous variant and giant cell variant have been described in the literature [1], [2], [18].

Fibrosarcomatous transformation is a particularity that must be recognized and reported. The areas are shown by an abrupt transformation of conventional DFSP to areas which present herringbone pattern, increased cellularity, increased mitotic count and atypia. These areas are seen on the usual stain and can also be highlighted by immunohistochemistry reactions. Frequently, the fibrosarcomatous areas are negative to CD34 or its expression is diminished.

Rare cases of DFSP can exhibit different cytological aspects. For example, the cells can lose the spindle shape and look round or epithelioid. In these tumors, the immunohistochemistry, history of the patient, clinical and paraclinical data are all important for establishing the diagnosis. Round cell sarcomas involving the soft tissue

of different body areas must be excluded (for example, rhabdomyosarcoma, peripheral neuroectodermal tumors, synovial sarcoma). [19]

The most important part of DFSP's treatment is complete surgical excision. Mohs micrographic surgery (MMS) approaches. This technique involves surgical excision of the tumor and continuous analysis under the microscope until the tumor is completely removed and negative surgical margins are achieved. In severe forms, radiation therapy and Imatinib are also treatments that can be taken into consideration to prevent recurrence or dissemination in fibrosarcomatous cases. [20]

4. Conclusion

Dermatofibrosarcoma protuberans (DFSP) is a rare yet clinically significant soft tissue tumor with high risk for local recurrence. The case presented highlights the importance of early diagnosis and surgical intervention to prevent recurrence and complications. In both primary and recurrent tumors, histopathological examination, supported by immunohistochemistry, was critical for accurate diagnosis and differentiation from other similar soft tissue neoplasms.

This case underscores the aggressive nature of recurrent DFSP, characterized by infiltrative growth, a higher mitotic index, and challenging surgical margins. While complete surgical excision remains the most important part of the treatment, recurrence in challenging anatomical locations may require multidisciplinary approaches.

Long-term follow-up is essential to manage any subsequent complications or recurrence. Further research is needed to develop better diagnostic and therapeutic options for this multifaceted tumor.

The particularities of this case reveals the local aggressivity of DFSP even without fibrosarcomatous transformation and contribute significantly to the field of soft tissue tumors by giving detailed insights regarding the outcome and clinicopathological characteristics of this entity.

Acknowledgements

No acknowledgments to declare.

References

1. WHO Classification of Tumours Editorial Board. Soft tissue and bone tumours. Lyon (France): International Agency for Research on Cancer; 2020. (WHO classification of tumours series, 5th ed.; vol. 3). <https://publications.iarc.fr/588>.
2. WHO Classification of Tumours Editorial Board. Skin tumours [beta version ahead of print]. Lyon (France): International Agency for Research on Cancer; 2023. (WHO classification of tumours series, 5th ed.; vol. 12). Available from: <https://tumourclassification.iarc.who.int/chapters/64>
3. Allen A, Ahn C, Sangüeza OP. Dermatofibrosarcoma Protuberans. *Dermatol Clin*. 2019;37(4):483-488. doi:10.1016/j.det.2019.05.006
4. Vitiello GA, Lee AY, Berman RS. Dermatofibrosarcoma Protuberans: What Is This?. *Surg Clin North Am*. 2022;102(4):657-665. doi:10.1016/j.suc.2022.05.004
5. Acosta AE, Vélez CS. Dermatofibrosarcoma Protuberans. *Curr Treat Options Oncol*. 2017;18(9):56. doi:10.1007/s11864-017-0498-5
6. Reha J, Katz SC. Dermatofibrosarcoma Protuberans. *Surg Clin North Am*.

- 2016;96(5):1031-1046.
doi:10.1016/j.suc.2016.05.006
7. Rust DJ, Kwinta BD, Geskin LJ, Samie FH, Remotti F, Yoon SS. Surgical management of dermatofibrosarcoma protuberans. *J Surg Oncol.* 2023;128(1):87-96.
doi:10.1002/jso.27258
 8. Mujtaba B, Wang F, Taher A, et al. Dermatofibrosarcoma Protuberans: Pathological and Imaging Review. *Curr Probl Diagn Radiol.* 2021;50(2):236-240.
doi:10.1067/j.cpradiol.2020.05.011
 9. Sleiwah A, Wright TC, Chapman T, Dangoor A, Maggiani F, Clancy R. Dermatofibrosarcoma Protuberans in Children. *Curr Treat Options Oncol.* 2022;23(6):843-854.
doi:10.1007/s11864-022-00979-9
 10. Heymann WR. Dermatofibrosarcoma protuberans recurrence: Size matters. *J Am Acad Dermatol.* 2023;89(5):909-910.
doi:10.1016/j.jaad.2023.09.001
 11. Kuhlmann C, Ehrl D, Taha S, et al. Dermatofibrosarcoma protuberans of the scalp: Surgical management in a multicentric series of 11 cases and systematic review of the literature. *Surgery.* 2023;173(6):1463-1475. doi:10.1016/j.surg.2023.02.026
 12. LeBlanc J, Chan C, Zedlitz A. Dermatofibrosarcoma protuberans. *Cutis.* 2017;100(1):E6-E7.
 13. Lim SX, Ramaiya A, Levell NJ, Venables ZC. Review of dermatofibrosarcoma protuberans. *Clin Exp Dermatol.* 2023;48(4):297-302.
doi:10.1093/ced/llac111
 14. Myers DJ, Fillman EP. Dermatofibroma. Treasure Island (FL): StatPearls Publishing; February 29, 2024.
 15. Khamdan F, Brailsford C, Dirr MA, Sagut P, Nietert PJ, Elston D. Dermatofibroma Versus Dermatofibrosarcoma Protuberans: A Nuclear Morphology Study. *Am J Dermatopathol.* 2023;45(9):631-634.
doi:10.1097/DAD.0000000000002526
 16. Bandyopadhyay MR, Besra M, Dutta S, Sarkar S. Dermatofibroma: Atypical Presentations. *Indian J Dermatol.* 2016;61(1):121. doi:10.4103/0019-5154.174131
 17. Sadullahoğlu C, Dere Y, Atasever TR, Öztöğ MT, Karaaslan Ö. The Role of CD34 and D2-40 in the Differentiation of Dermatofibroma and Dermatofibrosarcoma Protuberans. The Role of CD34 and D2-40 in the Differentiation of Dermatofibroma and Dermatofibrosarcoma Protuberans. *Türk Patoloji Derg.* 2017; 1(1):223-227.
doi:10.5146/tjpath.2017.01402
 18. Tariq MU, Din NU, Abdul-Ghafar J, Park YK. The many faces of solitary fibrous tumor; diversity of histological features, differential diagnosis and role of molecular studies and surrogate markers in avoiding misdiagnosis and predicting the behavior. *Diagn Pathol.* 2021;16(1):32. doi:10.1186/s13000-021-01095-2
 19. Sharma S, Kamala R, Nair D, et al. Round Cell Tumors: Classification and Immunohistochemistry. *Indian J Med Paediatr Oncol.* 2017;38(3):349-353.
doi:10.4103/ijmpo.ijmpo_84_16
 20. Loghdey MS, Varma S, Rajpara SM, Al-Rawi H, Perks G, Perkins W. Mohs micrographic surgery for dermatofibrosarcoma protuberans (DFSP): a single-centre series of 76 patients treated by frozen-section Mohs micrographic surgery with a review of the literature. *J Plast Reconstr Aesthet Surg.* 2014;67(10):1315-1321.
doi:10.1016/j.bjps.2014.05.021