

ELEMENTS OF CLINICAL PATHOLOGY AND ELECTROCARDIOGRAPHIC CHANGES IN TRICHINELLOSIS

D. COSTACHE¹ C. COSTACHE² A.T. BOGDAN³

Abstract: *The presence of cardiological manifestations in trichinellosis infections in humans is frequently associated with severe clinical forms of the infection. Very frequently, the clinical condition manifests itself infraclinically, but it is only by means of paraclinical investigations that we can establish the correct diagnosis. The cardio-vascular manifestations include: trichinous myocarditis characterised by tachycardia, cardiac noise, dirotic pulse, global increase of the heart, mitral systolic murmur which is sometimes combined with extra-systole. Serious clinical issues could be moderate dispnea (difficult breathing), palpitations, angor pectoris crises and low blood pressure.*

Key words: *trichinellosis, myocarditis, electrocardiography.*

1. Introduction

It is well known that trichinellosis may be accompanied by heart lesions. These may sometimes be very obvious, some other times clinically non-perceivable, being discovered only by means of a series of electrocardiograms or when necropsy is performed.

Once myocarditis emerged, it develops independently of the basic disease/infection. Sometimes its evolution may be accompanied by permanent endotelio-ventricular lesions, such as irreducible heart insufficiency caused by a high amount of produced eozynophils, most probably through an immunologic

mechanism. In severe cases some other problems may occur, such as myocardial infarction (heart attacks), intra-ventricular trombosis, cardial insufficiency which has been so far compensated by means of digitalic treatment, trichinous pericarditis, peripheral acute ischemy, peripheral thrombophlebitis, and even skin, digestive or gastrointestinal hemorrhage.

In decompensated forms, which are seldom encountered and only among those suffering from chronic cardiopathy, dispnea, lung congestions, sometimes pulmonary edema, liver stasis, or generalised edemas. Trichinous myocarditis presupposes the possibility of acute decompensation which could classify

¹ *Transilvania* University of Braşov, Department of Infectious Disease, postdoctoral researcher at School for Livestock Biodiversity and Food Biotechnology, Bucharest, Romania within Romanian Academy.

² Department of Anatomy, *Transilvania* University of Braşov.

³ Romanian Academy, National Institute for Economical Research (INCE)-Center for Agroforestry Biodiversity Study and Research (CSCBA)- Postdoctoral School for Livestock Biodiversity and Food Biotechnology, Bucharest, Romania.

as acute cardiocirculatory insufficiency of the circular shock type, but which can lead to acute accidents such as collapse or syncope with sudden death. These situations impose a very careful investigation of the function of the cardiovascular apparatus, both during the disease, as well as during the early or late convalescence.

2. Objectives

In our study we have focused on the clinical manifestations of the cardiovascular apparatus; we have interpreted the cardiac signs and symptoms according to the clinical form of trichinellosis.

3. Materials and Methods

Of the 327 patients we investigated in a time span of 10 years (1997-2007) within the Infectious Diseases Hospital in Brasov, 26 knew that they were suffering from a vascular or metabolic chronic cardiac disease. These particular patients were removed from the study in order for us to correctly interpret the cardiac manifestations that had emerged during the evolution of trichinellosis.

The highest percentage (25%) of patients with cardiac antecedents have been recorded in the case of severe trichinellosis; in the milder form, the percentage was smaller (9.61%), while in the medial and sub-medial forms we recorded 7.69%.

The high number of patients with cardiovascular problems associated to the severe forms of trichinellosis could explain the higher frequency of cardiac complications encountered in this clinical form. If correct etymology is ignored and if we focus on the clinical symptoms only, we might run the risk of delaying the antiparasitic therapy, which will favour the decompensation of other organs and systems. This is very possible, considering that trichinellosis is a condition that causes gradual and serious changes in the physiology and chemistry of all organs and tissues, operating even on nucleic acid and histamine.

4. Results and Discussion

Cardiac auscultation has proved changes of the heart sounds in 19% of the patients (see fig.1).

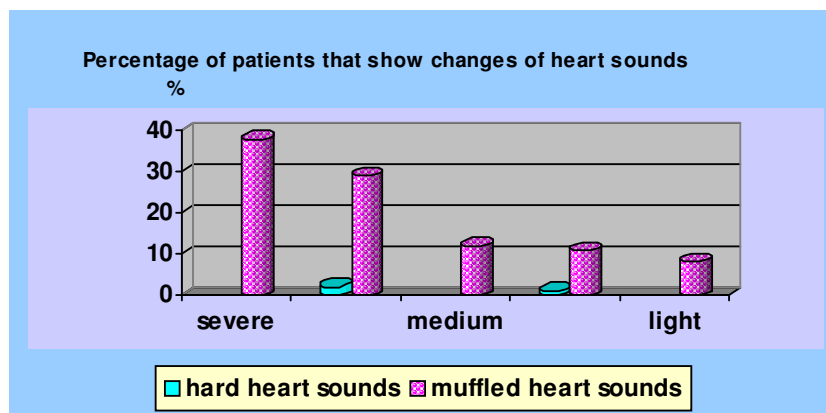


Fig. 1. Percentage of patients that show changes of heart sounds

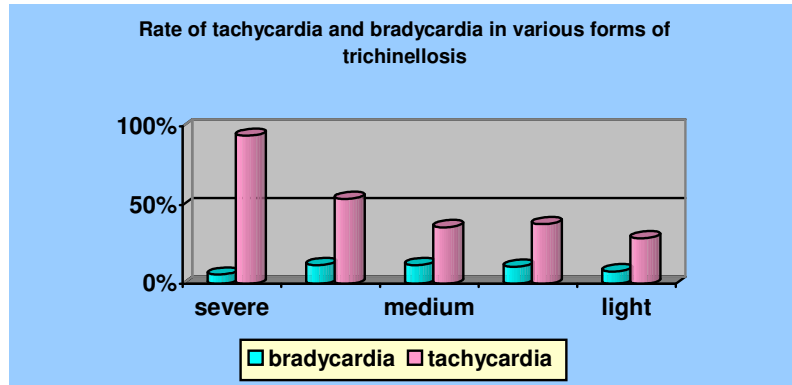


Fig. 2. Rate of tachycardia and bradycardia in trichinellosis

In all forms of trichinellosis we have identified muffled heart sounds, the highest rate being recorded in the severe and medium forms - 67%. In the medium and light forms, hard heart sounds were very scarce, i.e. around 3%.

In the cases we investigated we tried to point out the basic alterations of the heart beat. The most frequent changes were those of the ventricular beats. Thus, diagram 2 below shows that both tachycardia and bradycardia were recorded in all clinical forms of trichinellosis, tachycardia having the highest rate of occurrence.

Tachycardia is present in the highest percentage in the severe form in 94% of the patients and in the mildly severe form in 54% of the cases. Bradycardia has the highest percentage (12%) both in the mildly

severe and in the medium forms, having the lowest rate (6%) in the severe form.

Of the 327 patients we investigated between 1997- 2007, 12% had mitral and tricuspid murmurs when they were taken to hospital. In the severe form, both types of cardiac murmurs had the same rate (13%). Starting from the severe form of trichinellosis, the curve representing the percentage of patients with tricuspid murmur has a descending trajectory towards the sub-medium form, where it reaches 2%.

Diagram 3 shows that the mitral murmur occurs to the same extent (8%) in the medium and sub-medium forms. Such murmurs have not been identified in the patients with light forms of trichinellosis.

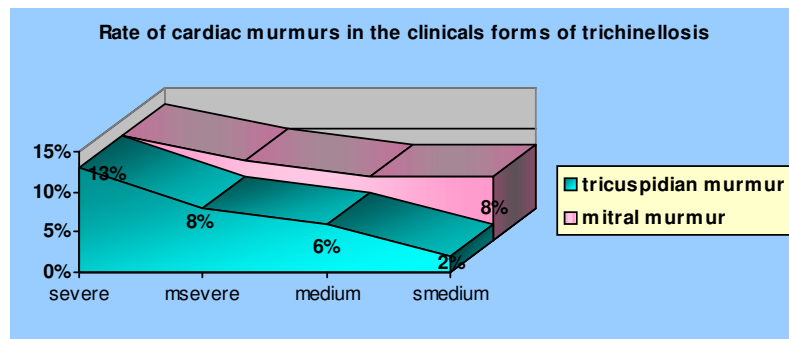


Fig. 3. Rate of cardiac murmurs in trichinellosis

In diagram 4 one can notice that in all clinical forms of trichinellosis, both low blood pressure and stage I high blood pressure appeared. The most frequent changes of blood pressure occurred in the severe and mildly severe forms, where

hypotension represents 38%, while stage I hypertension represents 25%.

Stage II hypertension was recorded in a small percentage (7%) and only in severe and medium forms.

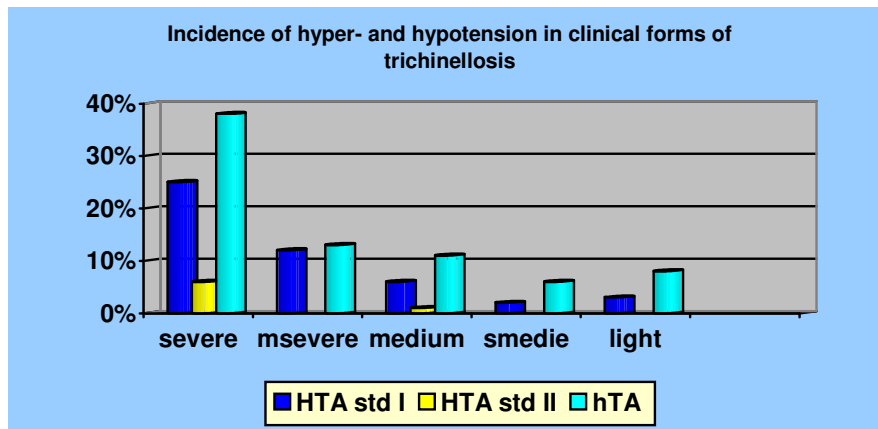


Fig. 4. *Incidence of hyper- and hypotension in trichinellosis*

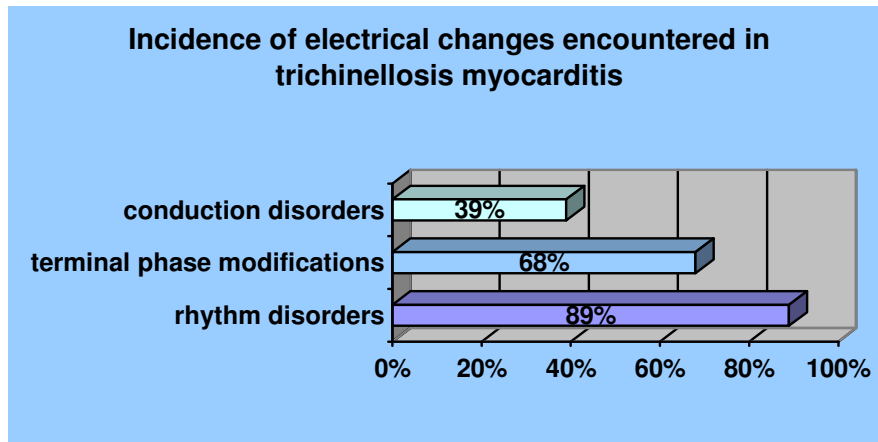


Fig. 5. *Incidence of electrical changes in trichinellosis myocarditis*

Mendell G.L. and Clinton M. has recorded high blood pressure in 18% of his patients; in our study the percentage is smaller, of only 8% [3]

In the study we performed on 327 patients in the Infectious Diseases Hospital in Brasov, in between 1997-2007, we also

included our observations concerning myocarditis in trichinellosis, but they were the topic of another paper. The fact that many of the patients were under 42 years of age and that the incidence among children has increased poses considerable

problems as concerns the etiological diagnosis.

In our study, from the 327 patients, only 5% showed clinical signs of myocarditis that were also confirmed by ECG; 19 % of these patients had the severe form of trichinellosis. The clinical signs of myocarditis appeared relatively late, 2-3 weeks after the emergence of the infection and usually as an additional element of a clinical condition manifested through fever, gastrointestinal disorders, myalgia, periorbital edemas or rash.

Myocarditis may have a subclinical evolution or may have different manifestations, such as palpitations, dispnoea, heart beat changes (tachycardia, bradycardia with or without ventricular extrasystole), muffled heart sounds, accelerated rhythm, recent myral insufficiency murmur, as well as low high pressure or high blood pressure [2, 4].

Cardiac sonogram was performed on 32 patients. This revealed pericardial effusion in the case of one patient with trichinellosis myocarditis, the other pathological changes occurring in the case of cardiac diseases associated with trichinellosis.

As for the signs revealed by ECG, these need to be known, because in many cases they are the only signs of myocarditis (infraclinical evolution) [1].

The most frequent electrical changes in myocarditis encountered in our study are listed below (see diagram 5):

- atrial or/and ventricular extrasystoles, paroxistic tachyarrhythmia (in 89% of the cases);
- terminal phase changes with ST segment elevation; levelled or negative T waves (in 68% of the cases)
- atrio-ventricular or interventricular conduction disorders with atrio-ventricular block or branch block (in 39% of the cases);

Cotran R.S., Kumar V. showed that the most frequent electrocardiographic changes encountered in trichinellosis are extrasystoles, increase of the PR interval, small QRS complexes with intraventricular block, and the levelling or inversion of the T wave [2].

In a prospective ecocardiographical study it have found cardiac modifications in 18% of their patients, the most frequent of these being terminal phase modifications and systolic dysfunction [3].

Not all ECG changes that appeared during the trichinella infections should be attributed to myocarditis; some may be cause by fever, hypoxia, acidosis, tachycardia, ischemia or drugs [1].

The blatistocardiography employed in investigating trichinellosis myocarditis brought to light alterations of Brown II, III, and IV type in 47% of the investigated cases, a percentage slightly more active than in the case of ECG, the examination being completed by lung X-rays and the timing of the pulmonary circulation [4].

Capilaroscopic research in trichinellosis shows the existence of a generalised vasculopathy, some of the forms being associated with myocarditis [3, 4].

Unfortunately, we could not perform such investigations in order to compare our date to previous research findings and to acquire additional knowledge concerning the evolution of the cardiovascular manifestations as compared to the clinical form of trichinellosis evolution.

5. Conclusions

The conclusion of this study, which may be applied in practice, could be drawn by summarizing the clinical and electrocardiographic data in close relationship to the clinical form of trichinellosis, as shown in the table 1 below:

Cardiovascular manifestations in trichinellosis

Table 1

ALARMING SIGNS		NON-ALARMING SIGNS	
CLINICAL	PARACLINICAL	CLINICAL	PARACLINICAL
<ul style="list-style-type: none"> - muffled heart sounds - orifice murmurs - Eo > 3500 cel/mm³ - angor pectoris crises - extreme tachycardia and bradycardia - Hypertension stage I - Hypertension stage II - hypotension - myocarditis - pericarditis - cardiac insufficiency - age < 42 years - children 	<ul style="list-style-type: none"> - CPK, LDH₄, LDH₅ - ECG increases; - heart rhythm disturbances - end phase disturbances - conduction disturbances 	<ul style="list-style-type: none"> - rhythmical heart beats - moderate bradycardia - sinus tachycardia - Hypertension stage I 	<ul style="list-style-type: none"> - increases of TGO - Eo < 3500 cel/mm³

1. Heart problems in trichinellosis may have different manifestations, some being subclinical, and others really serious which have to be interpreted depending on the clinical form of trichinellosis.
2. The ECG alterations occurring in infectious diseases appear basically in the second part of the disease evolution, preceding the clinical syndrome
3. There is no parallelism between the clinical evolution and the ECG signs.
4. Most of the cases of myocarditis covered by our study were clinically non-apparent; the electric changes brought forth by electrocardiological monitoring proved to have an infraclinical evolution.
5. The severe cases of myocarditis have shown muffled heard sounds, mitral orifice or tricuspid orifice murmurs, considerable tachycardia, but also extreme bradycardia.

Acknowledgements

The authors are grateful to Professor Doctor Bela Fazakas for his scientific support.

References

1. Capo, V., Despommier, D.D.: *Clinical aspects of infection with Trichinella spiralis*,. In: Clinical Microbiology Revue 1996, 9(1) : 47-54.
2. Cotran, R.S., Kumar, V., Robbins, S.L.: *Trichinosis*. In: Robbins Pathologic Basis of Disease 5th, Philadelphia, W.B. Saunders, 1994 : 197-199; 562-564.
3. Mandell, G.L., Bennett, J.E., Dolin, R.D.: *Tissue nematodes, Principles and Practice of Infectious Diseases*. In: New York ,Wiley Medical 2000 : 2943-2945.
4. Rebedea, I.: *Trichineloză, Boli Infecțioase, (Trichinellosis, Infectious Diseases)*. Bucharest. Medical Publishing House 2000 : 255-256.