

ATYPICAL KAWASAKI DISEASE CASE REPORT

A. DEACONU¹ D. VODĂ²
B. POPOVICI² M. ISPAS¹

Abstract: *Kawasaki disease (KD) is a systemic acute vasculitis, characterized by fever, bilateral non-exudative conjunctivitis, redness of the tongue, lips and oral mucosa, changes in the extremities, cervical lymph node, and polymorphic exanthema. The diagnostic criteria for Kawasaki disease are fever and at least four of the above five symptoms. Aneurysms and stenosis of coronary arteries are the most severe complications. In many cases, the clinical criteria for KD are not all present (incomplete or atypical KD). Particularity of the presented case is given by the initial interpretation of exanthema as allergy skin rash at Cefuroxime. Arthritis was initially considered reactive or in the Systemic Juvenile Rheumatoid Arthritis, leading to delay of the positive diagnosis. Appearance in the convalescent phase of desquamation of the fingers, took the diagnosis to KD. Treatment with Aspirin was initiated in the 11-day fever. The prognostic of the case is good because there are no cardiac complications.*

Key words: *Immunoglobulin, Aspirin, coronary aneurysm, exanthema, Kawasaki disease, thrombocytosis, arthritis, fever.*

1. Introduction

Tomisaku Kawasaki discovered his first case at a four-year-old child (Red Cross Hospital in Tokyo, Japan in January, 1961). 85% of the cases affect children below the age of 5, the ratio between boys and girls being 1.7. KD consists of generalized systemic vasculitis, affecting predominantly medium-sized vessels [2]. The diagnostic criteria for Kawasaki disease are fever and at least four of the five symptoms below. The fever is unresponsive to antibiotic, lasts for approximately ten days, but may range from 5 to 25 days [3], [4].

The five symptoms are:

1. Bilateral bulbar conjunctival injections not accompanied by suppuration [3].
2. Changes in the mucosa of the oropharynx (bright red, swollen lips with vertical cracking and bleeding, red oropharynx, strawberry tongue) [3].
3. Changes of the peripheral extremities (erythema of the palms and soles, which is often accompanied by painful, brawny edema of the dorsa of the hands or feet in the acute phase, being followed by desquamation of the fingers) [3].

¹ Faculty of Medicine, *Transilvania* University of Braşov.

² Children Hospital of Braşov.

4. The polymorphous rash described was: scarlatiniform, macular, papular, multiforme, and purpuric. The rash is never bullous or vesicular [3].
5. Cervical lymphadenopathy (more than 1.5 cm diameter), without suppuration [3].

Incomplete KD should be considered in the case of all children with unexplained fever for more than 5 days, associated with 2 or 3 of the main clinical findings of KD [3]. The diagnosis of incomplete KD is based on echocardiographic findings [3], [6].

2. Case report

BAM patient, aged 1 year and 10 months, was hospitalized in Braşov between 04/01/2011 - 04/13/2011 (FO: 2956) for the following reasons: fever, marked fatigue, arthralgia.

Family history: maternal grandmother with epilepsy.

Physiological and pathological personal history: the second child, born at 39 weeks, G = 3400 g, born by caesarean section, APGAR = 10, jaundice 7 days, fed artificially from 4 months, vaccinations performed.

Pathological history: atopic dermatitis, bronchiolitis at the age of 2 months.

Debut symptoms were at 03/20/2011 with cough, inspiratory dyspnea. The first diagnosis was laryngitis, to which the family doctor recommended Ibuprofen, Adrenaline aerosol. Because of fever on 03/22/2011 he is examined again by her family doctor who recommended Azytromicine, Ibuprofen, Paracetamol.

ORL consultation 03/24/2011 - congestive otitis (he continues the treatment).

Patient was consulted in Emergency Room (ER) in 03/25/2011 (chest x-ray is normal) and Cefuroxime is recommended. After 3 doses of Cefuroxime allergic maculo-erythematous exanthema appears

for which he goes back to ER. Dexamethasone and antibiotic (Amoxicillin clavulanat) are given because fever and productive cough persist.

On 28.03.2011 the patient is examined by the pediatrician, presenting fugitive erythema, persistent fever. Dexamethasone, Ibuprofen and Paracetamol are administered.

Approximately 3 days prior to admission in hospital he experienced pain in the lumbar region during the night and on admission aches in the legs with functional impotence.

On 03/31/2011 Ceftazidime intravenous therapy is initiated and solution-Medrol. Persistent fever during this period lasted for 10 days and patient received 4 different types of antibiotics.

Physical examination on admission in hospital (04.01.2011): severe general condition, G = 15 kg, fever 38.5 °C; suffering face, pale skin, cervical lymphadenopathy, discrete foot and right ankle swelling, skin superjacent warmer, marked functional impotence, limped walk, vesicular bilateral murmur, well beaten heart, throat congestion, red lips, strawberry tongue, slender abdomen, no signs of meningeal irritation.

Laboratory investigations in dynamics: intense biological inflammatory syndrome (leukocytosis, neutrophilia, acute phase reactants, elevated erythrocyte sedimentation rate), persistent thrombocytosis.

Leukocytes = 17200/mm³, Neutrophils = 65.8%, Lymphocytes = 24.5% = 8.3% Monocytes, Basophils = 0.2%, RBC = 4670000/mm³, Hgb = 12.1 g / dl; Hct = 34.9%, MCV = 74.7 fl, MCH = 25.9 pg, MCHC = 34.7 g / dl, Platelets = 865,000 / mm³.

Inflammatory syndrome: ESR = 70 mm/1h, fibrinogen = 640 mg; CRP = 7.35 mg / dl.

The other investigations were normal: glucose = 75 mg / dl, protein = 7.1,

ALT / AST = 15/29, urea = 8.1 mg / dl , creatinine = 0.45 mg / dl, Calcium = 9.53 mg / dl; Fe = 43 g / dl, FR = 51 IU / ml = 68 mm/h ESR, CRP = 0.73 mg / dl, fibrinogen = 410 mg, LDH = 449 U / l, urea = 10.8 mg / dl, creatinine = 0.57 mg / dl, ALT / AST = 8/27U/l, serum calcium = 10.17 mg / dL, protein = 8.1 g / dL, ASLO=56 UI;

The immunograma was normal.

Screening septic - negative culture (pharynx, urine, blood, stool).

Immunological and serological investigations were negative: antibodies antinuclear, antibodies double-stranded antiADN.

25.03.2011 Pulmonary radiography performed prior to admission = increased perihilar interstitial drawing.

04/03/2011 Orthopedic consult = limping without obvious inflammatory signs in the leg joints. Recommendations: pelvis X-ray, further antibiotic treatment. No articular puncture was performed.

04/03/2011 Pelvis X-ray = no structural changes in the pelvis bone

04/04/2011 Eye exam: normal anterior segment, with no evidence of iridocyclitis.

Surgical consult 04/04/2011: pelvis X-ray shows no signs of arthritis of the pool

04/05/2011 Echography of abdominal: organs appear normal without abdominal lymphadenopathy, without free fluid in the peritoneal cavity.

04/06/2011 Ultrasound = no collections at the hip joints bilaterally.

04/08/2011 Neurological consult: no objective signs of paresis of peripheral nerves in the legs. Negative Babinski sign. Slightly enlarged walk without support, light weakness, insecurity.

11/04/2011 Echocardiography: normal heart ultrasound.

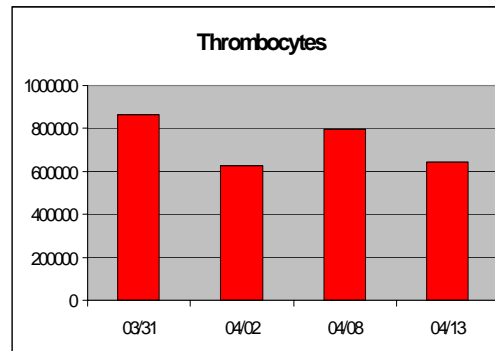


Fig. 1. *Evolution of thrombocytes*

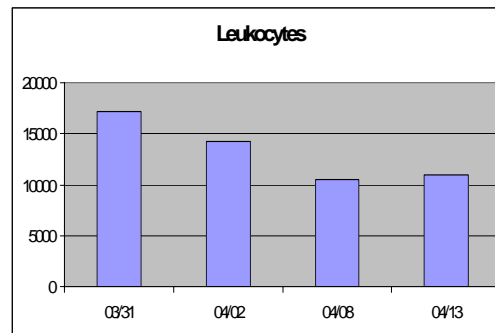


Fig. 2. *Evolution of leukocytes*

In fig. 1 and fig. 2 we can see the evolution of thrombocytes and, respectively, leukocytes during treatment.

In the first three days of hospitalization the general condition is poor with feverish, pale skin, restlessness, swelling of the metatarsophalangeal joint bilaterally, without local redness, skin superjacent warmer, functional impotence, limping, joint pain at the hip, erythematous maculopapular rash on the chest (1 day).

The treatment established was: antibiotherapy (10 days Cefazidim, Gentamicin 6 days), therapy with Ibuprofen (9 days), Paracetamol (first two days).

After treatment: satisfactory general condition, pale skin with no rash, but with discrete palmar erythema and discrete desquamation of the fingers (raised in 04/11/2011), without joint swelling, stands alone on her feet.

2.1. Differential diagnosis

Interpretation of the case: initially, after clinical and laboratory examinations, the following diagnoses were discussed:

1. The Systemic form of Juvenile Rheumatoid Arthritis: a) clinically prolonged fever, erythematous rash that occurred at home (after administration of Cefuroxime), marked fatigue, swelling of the metatarsophalangeal joints bilaterally, accompanied by functional impotence, without local redness, b) laboratory findings: leukocytosis, thrombocytosis, inflammatory syndrome (ESR, CRP, fibrinogen, FR with high values), normal eye examination, orthopedic consultation (limping without obvious signs of inflammation in the joints). For these reasons antibodies antinuclear were harvested (negative). Antibodies anti DNA HLA DR4/DR1 were also harvested.
2. Reactive arthritis: a) anamnestic respiratory infection, otitis (failure treated with antibiotics at home), b) clinical :fever, aches in the joints of lower limbs with functional impotence, c) laboratory findings: leukocytosis, acute phase reactants with high values, negative blood culture, urine culture negative, surgical consult (limping without obvious inflammatory signs in the joints); d) therapeutic sample positive (antibiotic and therapy with ibuprofen improved symptoms and decreased inflammatory syndrome).
3. KB is most frequently confused with infectious rash of children caused by the measles virus, echoviruses and adenoviruses, which can cause signs of mucocutaneous inflammation. They typically have less evidence of systemic inflammation [3].
4. Toxin-mediated diseases, especially infection with beta-hemolytic *Streptococcus* and staphylococcal toxic

shock syndrome are unaffected eye and joint, typical of KB [3].

5. Leptospirosis is an infectious disease to be considered in the differential diagnosis of KB. Headache and gastrointestinal complaints are typical manifestations of this infection [3].
6. Reactions to drugs - such as Stevens-Johnson syndrome or serum sickness - can mimic KB [3].
7. Allergy to mercury (acrodinia, pink disease) shows a part of some manifestations of KB, including fever, rash, swollen hands and feet, desquamation and photophobia [3].

2.2. Review of diagnosis

Since in evolution patient presented discrete palmar erythema and desquamation of the fingers (04/11/2011) (specific to convalescent phase), Kawasaki disease has been discussed and the treatment with aspirin was introduced (30 mg / kg / day).

Positive diagnosis is based on: a) anamnestic younger than 5 years (1 year and 10 months), b) male gender, c) presence of clinical manifestations at home accompanied by prolonged fever (approximately 11 days) and the presence of 4 criteria:

- Criterion 1: mucosal (red lips, strawberry tongue);
- Criterion 2: erythematous rash on the trunk first, then on the arms, on the metacarpophalangeal joints (initially interpreted as allergy at Cefuroxime), desquamation of the fingers;
- Criterion 3: hyperemia of both eyes increased during febrile periods;
- Criterion 4: cervical lymphadenopathy.

Laboratory investigations revealed in this case: leukocytosis with neutrophilia, inflammatory syndrome, thrombocytosis (865,000 / mmc), which are laboratory abnormalities described in KD.

Thrombocytosis is frequently seen after the first week of the illness and may be marked (1,000,000/mmc)[3][4].

During the acute phase of the illness, patients with KD could have: mild anemia, hypoalbuminemia, and elevated serum immunoglobulin E levels and elevated serum transaminases, sterile pyuria, proteinuria, plasma lipids changes (depressed level of cholesterol), cerebrospinal fluid could be characterized by pleocytosis with a predominance of mononuclear cells, and the synovial fluid could be inflammatory [3][4].

2.3. Evolution after hospitalisation

Clinical and Biological evaluation I (04/20/2011 - FO: 1599)

Good general condition, afebrile, normal skin color, without laterocervical adenopathy, vesicular murmur present bilaterally, rhythmic heart sounds, depressed abdomen, no joint swelling, normal gait.

Investigations: no inflammatory syndrome, no thrombocytosis, echocardiography and electrocardiography were normal.

WBC = 10,300 / mmc, Neutrophils = 48.6%, lymphocytes = 40.8%; Monocytes Eosinophils = 8.1% = 1.7% = 0.8% Basophils. RBC = 4850000 / mm³, Hgb = 12.4 g / dl, Hct = 36.6%, MCV = 75.5 fl, MCH = 25.6 pg, platelets = 589000/mmc. ESR = 45 mm/h, Fibrinogen = 479 mg%, blood sugar = 67 mg / dl, urea = 12.8 mg / dl, creatinine = 0.55 mg / dl, CRP = 0.99 mg / dl; Iron = 45 yg / dl, LDH = 681 U / L, ALT / AST = 6/35 U / l.

Recommendations: treatment with Aspirin 75 mg (total dose = 10 mg / kg / day), after meals for 2 weeks.

The patient was on 04/26/2011 at Pediatric Clinic of Cluj Napoca for biological and clinical cardiologic (cardiac ultrasound was normal).

Clinical and Biological Control II (FO 9044, 11/18/2011-11/20/2011):

Physical examination on admission: good general condition, afebrile, cardio-respiratory balanced, without subjective complaints.

Investigations: no inflammatory syndrome, normal level of thrombocytes, echocardiography and electrocardiography were normal.

Hb = 13.5 g / dl, MCV = 73 fl, MCH = 27 pg, MCHC = 37 g / dl, Tr = 370000/mmc, Fb = 171 mg, ESR = 5 mm / hour, CRP = 0.4 mg, ASO = 50 u / l SGOT = 15 U / L, SGPT = 37 U / L, Na = 140 mmol / l, K = 4.5 mmol / l, Ca = 10.24 mg, Urea = 0.26 mg, Creatinine = 0.66 mg, L = 7750/mmc, N = 49.6%, Ly = 39.6%, Eo = 1.7%.

3. Discussions

Particularity of our case is given by the initial interpretation of exanthema as allergy skin rash at Cefuroxime. Arthritis was considered initially reactive or in the Systemic Juvenile Rheumatoid Arthritis, leading to delay of the positive diagnosis. Appearance in the convalescent phase of desquamation of the fingers, took the diagnosis to Kawasaki disease. The prognostic is good because there are no cardiac complications in this case.

A recent study revealed that there are 67 different genes associated with KD and involved in: endothelial dysfunction, platelet adhesion. Studies discovered a new family of proteins (S100) released by neutrophils and monocytes during the inflammatory cascade [2]. Proteins S100 act by binding to the endothelial cell receptor (RAGE). An inhibitory factor (s-RAGE) prevents the binding of protein S100A12 to the receptor. Level of s-RAGE is reduced especially in patients that do not respond to the treatment [3], [4].

In the initial stages of vasculitis in KD, there is edema of the endothelial and inflammation of the adventitia. Internal elastic lamina remains intact. There is initial neutrophilic inflammatory infiltrate, with mononuclear predominance of cytotoxic T lymphocytes CD8+ and immunoglobulin IgA [9]. Inflammatory activity remains for weeks and months with progressive fibrosis. Recent study had reported an association of the functional polymorphism of the inositol 1,4,5-triphosphate 3-kinase C (ITPKC) gene with immune activation of KD. ITPKC acts as a negative regulator of T-cell activation and may contribute to immune hyper-reactivity in KD [3][4][10].

Hemophagocytic syndrome (persistent fever, cytopenia, hepatosplenomegaly, liver dysfunction secondary) caused by excessive activation of macrophages, is a severe complication of KD [7].

Systemic inflammatory abnormalities in KD may be observed in many organs:

1. Musculoskeletal system: arthritis;
2. Gastrointestinal tract: diarrhea, vomiting, abdominal pain, hepatic dysfunction, hydrops of the gallbladder.
3. Central nervous system: aseptic meningitis, facial palsy, ataxia, encephalopathy, hemiplegia and cerebral infarction.
4. Respiratory tract: otitis media, pulmonary infiltrates.
5. Other findings: erythema and induration at Bacille Calmette Guerin (BCG) inoculation site, testicular swelling [3], [4].

Cardiac abnormalities possible find in KD was: pancarditis, coronary artery abnormalities, valvulitis. Patients with Kawasaki disease may have low cardiac output syndrome. Death is caused by acute myocardial infarction secondary to coronary thrombosis of aneurysm [3], [4].

In general, small and spindle-shaped aneurysms tend to suffer regression, whereas giant aneurysms have poor prognosis, including the risk of thrombosis. Coronary angiography offers a more detailed definition of coronary artery anatomy than the echocardiography [4].

There are factors that suggest severe prognosis of patient (high risk of forming aneurysms), which are:

- 1) duration of fever for more than 16 days,
- 2) recurrence of fever after at least 48 hours without it,
- 3) arrhythmia,
- 4) male gender,
- 5) age younger than 1 year,
- 6) presence of cardiomegaly and
- 7) laboratory affections such as platelet reduction, anemia and hypoalbuminemia [3], [8].

The peak of mortality is between 15 and 45 days from onset of the fever.

Treatment with Aspirin was initiated in our case in the 21-day fever (no ultrasound showed coronary aneurysms). Doses of Aspirin were used as medium because fever was remitted and inflammatory syndrome was in regression.

Aspirin in high doses has anti-inflammatory effect and in low doses it causes inhibition of platelet aggregation in children with KD [3]. In the acute phase, aspirin is used at 80-100mg/Kg/day dose, to maximize the anti-inflammatory effect of IVIG, but it does not reduce the frequency of coronary abnormalities. The duration of use of aspirin in high doses ranges from institution to institution. High doses of Aspirin are administered for 14 days starting 48-72 hours after the fever is gone. The reduction of Aspirin dose should be made to 3-5 mg/Kg/day and maintained for 6-8 weeks from the beginning of the disease [3], [4].

Studies have recommended the use of corticoids in the cases with no clinical response. The results after using corticoids are still controversial. Corticoid does not reduce the risk of heart abnormalities. The used regimen is pulse therapy with methylprednisolone 30 mg/kg/day for 3 days [3], [4]. There are no protocols directed to treating refractory KD.

Inhibitor of platelet glycoprotein IIb/IIIa receptor which has been used in patients in acute phase with large aneurysm, showed good progression of diameter of aneurysm [3], [4], [6], [11].

Treatment of the patients with coronary aneurysms aim prevents thrombosis and vessel stenosis. Low dose aspirin (3-5 mg / kg / day) is the main therapy recommended for the patient with small and medium aneurysms [6]. Other antiplatelet agents are also used (clopidogrel).

Immunoglobulins were not used in our case because they are indicated in the first 10 days of disease to prevent heart complications.

The efficacy of IVIG administered in the acute phase of the Kawasaki disease by reducing the prevalence of coronary artery abnormalities has been well established [3]. A single dose of 2 g/kg intravenous Immunoglobulin (IGIV) is the current standard of therapy. A variety of dose regimens has been used. The mechanism of action of IVIG includes: cross-linking of the Fc γ II and Fc γ III receptors on macrophages, induction of the immune inhibitory receptors, blocking of the interaction between endothelial cells and natural killer cells, augmenting the T-cell suppressor activity, suppression of antibody synthesis, neutralization of bacterial superantigens [3][4]. In vitro findings suggest that IGIV blocks endothelial-cell proliferation and the synthesis of adhesion molecules, chemokines [2] and cytokines [1], [3], [4], [10].

Vaccinations with attenuated live virus (measles, rubella, mumps and varicella) should be postponed at least for 11 months after administration of IVIG, owing to the reduced immunogenicity caused by the passive antibodies of the drug [3][4]. IGIV may also quickly normalize the inflammatory proteins of the acute phase, except the erythrocyte sedimentation rate (ESR), and may also improve the myocardial function [4].

A new class of biological agents, Infliximab, a monoclonal antibody against alpha tumor necrosis factor (TNF- α) is administered (reducing aneurysms) [6], [10].

4. Conclusions

The main challenge of the physician is early diagnostic because treatment in the first ten days modifies the prognosis of the disease.

Patients with KD should be reevaluated carefully for possible development of coronary artery disease. Heart manifestations may be exacerbated in the acute phase determining increase in long-term mortality and morbidity.

Children without cardiac complications of the Kawasaki disease appear to return to a good health state.

In many cases, the clinical criteria for KD are not all present. The concept of incomplete or atypical Kawasaki disease is used to describe the cases when experienced clinicians have patients with inflammatory disorders which do not meet the clinical case definition, but the echocardiogram documents a coronary abnormality.

Absence of sensitive diagnostic testing remains a major obstacle to correctly identifying patients with KD.

References

1. Abe, J., Jibiki, T., Noma, S., Nakajima, T., Saito, H., Terai, M.: *Gene expression profiling of the effect of highdose intravenous Ig in patients with Kawasaki disease*. In: *J Immunol.* 174 (2005), p. 5837-5845.
2. Breunis, W.B., Biezeveld, M.H., Geissler, J., Kuipers, I.M., Lam, J., Ottenkamp, J., et al.: *Polymorphisms in chemokine receptor genes and susceptibility to Kawasaki disease*. In: *Clin Exp Immunol.* 150 (2007), p. 83-90.
3. de Castro, P.A., Urbano, L.M., Costa, I.M.: *Kawasaki Disease*. In: *An. Bras. Dermatol.* 84 (2009) No. 4, p. 1-13.
4. Kim, D.S.: *Kawasaki disease*, In: *Yonsei Medical Journal* 47 (2006), No. 6, p. 759-772.
5. Hui-Yuen, J.S., Duong, T.T., Yeung, R.S.: *TNF-alpha is necessary for induction of coronary artery inflammation and aneurysm formation in an animal model of Kawasaki disease*. In: *J Immunol.* 176 (2006), p. 6294-6301.
6. Oishi, T., Fujieda, M., Shiraiishi, T., Ono, M., Inoue, K., Takahashi, A., et al.: *Infliximab treatment for refractory Kawasaki disease with coronary artery aneurysm*. In: *Circ J.* 72 (2008), p. 850-852.
7. Muise, A., Tallett, S.E., Silverman, E.D.: *Are children with Kawasaki Disease and prolonged fever at risk for Macrophage Activation Syndrome?* In: *Pediatrics* 112 (2003), p. 495-497.
8. Nakamura, Y., Yashiro, M., Uehara, R., Watanabe, M., Tajimi, M., Oki, I., et al.: *Use of laboratory data to identify risk factors of giant coronary aneurysms due to Kawasaki disease*. In: *Pediatr Int.* 46 (2004), p. 33-38.
9. Rowley, A.H., Shulman, S.T., Spike, B.T., et al.: *Oligoclonal IgA response in the vascular wall in acute Kawasaki disease*. In: *J Immunol.* 166 (2001), p. 1334-1343.
10. Wu, S.F., Chang, J.S., Wan, L., Tsai, C.H., Tsai, F.J.: *Association of IL-1Ra gene polymorphism, but no association of IL-1beta and IL-4 gene polymorphisms, with Kawasaki disease*. In: *J Clin Lab Anal.* 19 (2005), p. 99-102.
11. Williams R.V., Wilke V.M., Tani L.Y., Minich L.L.: *Does abciximab enhance regression of coronary aneurysms resulting from Kawasaki disease?* In: *Pediatrics.* 109 (2002), p.109-114.