

# PENILE PARAFFINOMAS AFTER SELF-INJECTION WITH KANAMYCIN OINTMENT

A. OANȚĂ<sup>1</sup> M. IRIMIE<sup>1</sup> Ș. ROGOZ<sup>2</sup>  
S. OANȚĂ<sup>3</sup> S. LUPU<sup>4</sup>

## **Abstract:**

**Introduction:** Penile paraffinoma, also called penile mineral oil granuloma, occur after injection into the penis of foreign bodies such as mineral or vegetable oils.

**Clinical case:** We present the case of a 29 years old male Gypsy patient who was consulted for nodules and fistulas on his penis. History revealed self-injection of kanamycin ointment into the penis body one year ago for the purpose of increasing the penile size. The diagnosis of penile paraffinoma was made. Circumcision with removal of nodules was performed. Histopathological examination by hematoxylin and eosin staining revealed the replacement of subcutaneous tissue with vacuolar lesions and a lymphocytic infiltrate with foreign-body giant cells.

**Discussion:** Mineral or vegetable oils injection into the penis or other skin areas can be followed after a period of several years by the appearance of foreign body reactions with lipogranulomas formation. Other complications such as infection, skin necrosis, ulceration, fistulization, invasion of corpus cavernosum, embolism and even death may occur.

**Conclusion:** The practice of injecting mineral and vegetable oils into the penile body, although abandoned in European countries, can be found in certain parts of the world and in certain social environments.

**Key words:** paraffinoma, mineral oil, lipogranuloma.

## **1. Introduction**

Penile paraffinomas occur after injection into the penis of foreign bodies such as mineral or vegetable oils. This practice was popular in the early twentieth century but in present is rarely seen due to serious complications that can result. We present the case of a male patient with penile paraffinomas occurred after injection of kanamycin ointment into the penis sheath.

## **2. Clinical case**

A 29 years old male patient referred to our clinic with multiple nodules located on the penis and phimosis. One year ago, he has self-injected subcutaneously into the penile sheath kanamycin ointment using a syringe, for the purpose to increase the penile size. On physical examination edema of the penis with the presence of multiple nodules of firm

---

<sup>1</sup> Department of Dermatology, *Transilvania* University, Braşov, Romania .

<sup>2</sup> Department of Histopathology, Children's Hospital, Braşov, Romania.

<sup>3</sup> Clinic of Dermatology from Târgu Mureş, Romania.

<sup>4</sup> Department of Urology, County Emergency Hospital, Braşov, Romania.

consistency with up to 2 cm in diameter were found, as well fistulas on the penile body and prepuce (Fig. 1, 2).

Based on history and clinical examination the diagnosis of penile paraffinomas was made. Under local anesthesia circumcision with removal of nodules was performed (Fig. 3, 4).

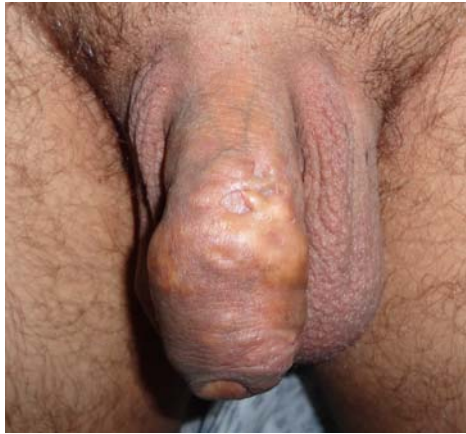

Fig. 1. *Multiple nodules and edema of the penis causing phimosis*

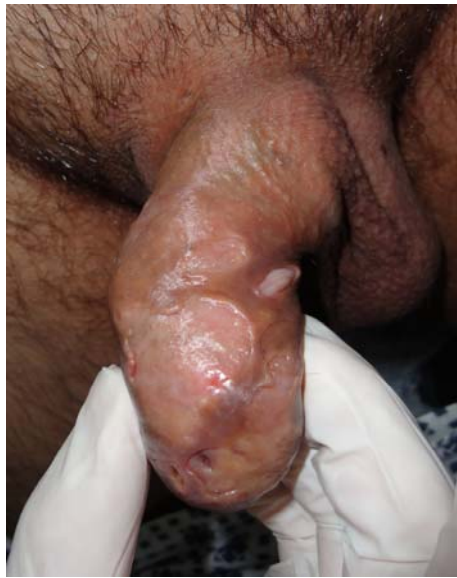

Fig. 2. *Fistulas on the penile body and prepuce*

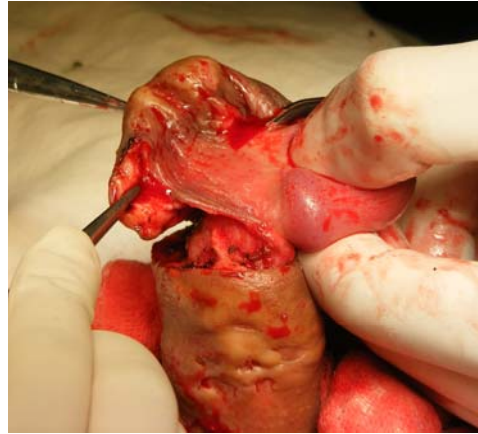


Fig.3. *Surgical excision of penile mass with circumcision*

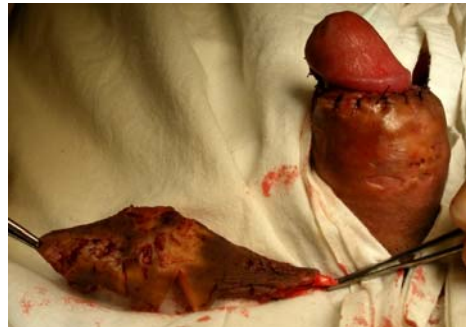

Fig. 4. *Postoperative appearance*

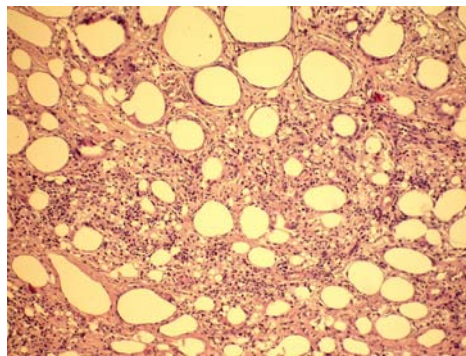


Fig. 5. *Histopathology: vacuolated spaces of varying sizes of the subcutaneous tissue with Swiss cheese pattern, surrounded by fibrous tissue and lymphocytic infiltrates containing multinucleated giant cells (hematoxylin-eosin stain with high magnification)*

Histopathological examination by hematoxylin and eosin staining revealed marked thickening of the reticular dermis and subcutaneous tissue replacement with numerous vacuoles of various sizes surrounded by fibrous tissue and the presence of lymphocytic infiltrates containing foreign-body giant cells (Fig. 5).

### 3. Discussions

The term “paraffinoma” has been suggested by Newcomer and Graham [17] for cases in which the injection of vegetable or mineral oils induced sclerosing lipogranuloma after a period of years from injection of the substance in any region of the skin [1, 2], [6], [9], [12], [20].

Penile paraffinoma, also called penile mineral oil granuloma, occur after injection into the penis of vegetal and mineral oils, paraffin, vaseline, or polydimethyl siloxane [2, 3, 6]. This practice, originally used in some primitive tribes, became popular at the beginning of twentieth century, for the purpose of augmenting the penis, the treatment of erectile dysfunction or the satisfaction of the sexual partner, being common especially in prisons and being due to the spirit of imitation [15], [19]. Subsequently, due to the occurrence of serious complications, this practice was mostly abandoned but is still currently in some Asian (such as Korea) and East European countries [5], [8], [11].

The first paraffin injection into the male genitalia was performed by Gersuny in 1899 into the scrotum of a man who had undergone bilateral orchiectomy for genital tuberculosis [7]. Subsequently, these injections were used for cosmetic purposes including cleft palate, wrinkles and other facial deformities, as well as muscle, breast or penile augmentation. In 1906, the first complications of this practice were reported, being cited two patients who develop disfiguring subcutaneous nodules of the face after injection of mineral oil for facial wrinkles [6]. Our patient was a young who in

the spirit of imitation and for the purpose of increasing the penis size has been self-injection kanamycin ointment into the penile sheath which resulted in appearance of multiple nodules and fistulas at the injection site. Side effects that may occur after these injections are sometimes serious consisting of infections, skin necrosis, ulceration, fistulization, local migration and corpus cavernosum invasion, embolism, blindness or even death [4], [13].

Paraffinomas form in humans because of the lack of enzymes that metabolize these exogenous oils leading to the appearance of foreign-body reactions inducing the formation of sclerosing lipogranulomas [6].

Histopathological appearance is characteristic due to the replacement of normal subcutaneous tissue by cystic spaces of various sizes compared to *Swiss cheese*. These cysts appear empty by hematoxylin and eosin staining, but using special stains (Sudan, osmic acid) on frozen tissue shows non absorbable oil that fills the cysts. These lakes of oil are surrounded by dense fibrous tissue and an inflammatory infiltrate including foreign-body giant cell reaction. Clinical induration is not only due to the extensive fibrosis but also to obstruction of lymphatic drainage caused by the presence of this nonabsorbable material in the lymph nodes.

The differential diagnosis of penile paraffinomas needs to be done, especially in the stage of fistulization and ulceration, with venereal diseases with granuloma formation, and in elderly patients with squamous cell carcinoma.

The most appropriate treatment of penile paraffinoma is surgery consisting of complete excision of the tumoral mass as early as possible [13, 14]. The primary wound closure is made by skin grafts or bilateral scrotal skin flaps [10, 11], [16], [18], [21]. Sometimes parts of foreign material may remain in the Buck's fascia or in the lymph nodes and complete removal is not always possible and can lead to relapses. Occasionally surgery

may be followed by skin necrosis. Antiseptics and antibiotics are used only in the case of secondary infections that may be associated with paraffinomas.

#### 4. Conclusion

The practice of self-injecting mineral and vegetable oils into the penis sheath, although abandoned in European countries, can be found in certain parts of the world and in certain social environments.

#### References

- Behar, T.A., Anderson, E.E., Barwick, W.J., Mohler, J.L.: *Sclerosing Lipogranulomatosis: a case report of scrotal injection of automobile transmission fluid and literature review of subcutaneous injection of oils*. In: *Plast Reconstr Surg* 1993;91(2):352-61.
- Black, M.M., Cunliffe, W.J.: *Oil Granuloma*. In: *Rook/Wilkinson/Ebling Textbook of Dermatology*, 6th ed. Champion RH, Burton JL, Burns DA et al., (eds.) Oxford: Blackwell Science Ltd: 1998: 2423.
- Boui, M., Vignes, S., de Kervilher, E., Farges, D.: *Case for diagnosis. Major swelling of the penis*. In: *Ann Dermatol Venereol*. 1999;126(4):339-40.
- Brauninger, W., Rauher, U., Hoede, N., Bork, K.: *Paraffin granuloma of the penis*. In: *Hautartz*. 1986;37(11):618-21.
- Christ, J.E., Askew, J.B. Jr.: *Silicone granuloma of the penis*. In: *Plast Reconstr Surg*. 1982;69:337-9.
- Cohen, J.L., Keoleian, C.M., Krull, E.A.: In: *Penile paraffinoma: self-injection with mineral oil*. In: *J Am Acad Dermatol*. 2001;45(6):S222-4.
- Gersuny, R.: *Harte und weiche Paraffinprothesen*. In: *Zentralbl Chir* 1903;30:1.
- Goryunov, V.G., Kudryavtsev, Y.V., Krendel, B.M., et al.: *Penile paraffinomas: etiology and pathogenesis*. In: *Urol Nephrol Moscow*, 1994;1:51-4.
- Hohaus, K., Bley, B., Köstler, E., Schönlebe, J., Wollina, U.: *Mineral oil granuloma of the penis*. In: *J Eur Acad Dermatol Venereol*. 2003;17(5):585-7.
- Jeong, J.H., Shin, H.J., Woo, S.H., Seoul, J.H.: *A new repair technique for penile paraffinoma: bilateral scrotal flaps*. In: *Ann Plast Surg*. 1996;37:386-93.
- Kim, D.S., Choi, H.Y.: *Penile paraffinoma: 39 cases*. In: *Korean J Urol*. 1992;33:551.
- Klein, J.A., Cole, G., Barr, R.J. et al.: *Paraffinomas of the scalp*. In: *Arch Dermatol*. 1985;121:382-5.
- Lee, T., Choi, H.R., Lee, Y.T., Lee, Y.H.: *Paraffinoma of the penis*. In: *Yonsei Med J*. 1994;35(3):344-8.
- Moon, W.C., Oh CH, Moon, Y.T., Kim, S.C.: *Penile paraffinoma*. In: *Korean J Urol* 1986;27:171-80.
- Moon, D.G., Yoo, J.W., Bae, J.H. et al.: *Sexual function and psychological characteristics of penile paraffinoma*. In: *Asian J Androl*. 2003;5:191-4.
- Muraro, G.B., Dami, A., Farina, U.: *Paraffinoma of the penis: one-stage repair*. In: *Arch Esp Urol*. 1996;49:648-50.
- Newcomer, V.D., Graham, J.H., Schaffert, R.R., Kaplan, L.: *Sclerosing lipogranuloma resulting from exogenous lipids*. In: *AMA Arch Derm*. 1956;73:361-72.
- Odintsov, B.P., Panikratov, K.D., Patsanovskii, A.G.: *The surgical treatment of penile oleogranulomas*. In: *Urol Nefrol (Mosk)* 1991;6:46-9.
- Pehlivanov, G., Kavaklieva, S., et al.: *Foreign-body granuloma of the penis in sexually active individuals (penile paraffinoma)*. In: *J Eur Acad Dermatol Venereol*. 2008;22(7):845-51.
- Sahin, A., Tekgul, S., Ergen, A., Basar, I., et al.: *Sclerosing lipogranuloma of the penis. A case report*. In: *Int Urol Nephrol*. 1991;23:595-8.
- Santos, P., Chaveiro, A., et al.: *Penile paraffinoma*. In: *J Eur Acad Dermatol Venereol*. 2003;17:583-4.