

A CASE OF PACHYDERMOPERIOSTOSIS IN THE CONTEXT OF FAMILIAL BLEPHAROPTOSIS

A. OANȚĂ¹ M. IRIMIE¹ S.H. MORARIU²

Abstract: Background: *Pachydermoperiostosis is a rare inherited disorder occurring mainly in males and represents 5% of all cases of hypertrophic osteoarthropathy. It is characterized by the clinical triad of finger clubbing, periostitis and pachydermia. Unlike the secondary forms of hypertrophic osteoarthropathy, pachydermoperiostosis is not associated with cardiopulmonary diseases or malignancies. Case report:* A 19-year-old male patient presented with thickening of the skin on the face, dorsum of the hands and feet, and skin folds of the face and scalp. Osteoarticular system examination revealed: finger clubbing and bilateral tibiotarsal joints swelling. Hematological, biochemical and endocrine tests were within normal limits. Computed tomography of cephalic extremity showed a normally sized sella turcica. Ultrasonography of tibiotarsal area revealed bilateral perimalleolar soft tissue swelling and irregular bone surfaces. The diagnosis of pachydermoperiostosis was made. Patient's mother and sister also presented with blepharoptosis but in the absence of other manifestations of pachydermoperiostosis. **Conclusion:** Presence in the family of patients with pachydermoperiostosis of other members with only minor signs of this disease suggesting that all the family members require a thorough physical examination for early diagnosis of incomplete or fruste forms of the disease.

Key words: *pachydermoperiostosis, hypertrophic osteoarthropathy, pachydermia, cutis verticis gyrata.*

1. Introduction

Pachydermoperiostosis (PDP) represents the primary form of hypertrophic osteoarthropathy (HOA), accounting for 5% of all HOA cases. First described in 1868, it is also known as primary hypertrophic osteoarthropathy or Touraine-Solente-Gole syndrome [4]. PDP is a rare hereditary disease characterized by finger clubbing, periostitis and pachydermia. Besides these three major criteria PDP may be found a series of minor criteria: hyperhidrosis, arthralgia, joint collections, gastric ulcer, cutis verticis gyrata, blepharoptosis, edema, seborrhea, acne.

Unlike the secondary forms of hypertrophic osteoarthropathy, PDP is not associated with cardiopulmonary diseases or malignancies. Usually, the progression of PDP ceases after about 10 years of evolution. We present the case of a young man diagnosed with PDP whose mother and sister presented with blepharoptosis.

2. Case report

A 19-year-old patient presented with skin folds on his forehead and scalp, occurred about 3 years ago, and bilateral tibiotarsal joint swelling occurred six months ago. Dermatological examination

¹ Faculty of Medicine, *Transilvania* University of Braşov.

² University of Medicine and Pharmacy Targu-Mures

revealed thickening of the skin on the forehead and the dorsal side of the hands and feet (Fig. 1, 2, 3), presence of skin folds on the forehead and scalp, prominent nasolabial folds and facial hyperseborrhea.

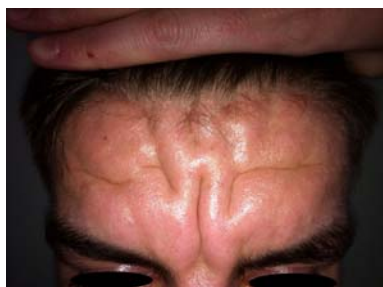


Fig. 1. Pachydermoperiostosis: thickening of the skin and skin folds on the forehead

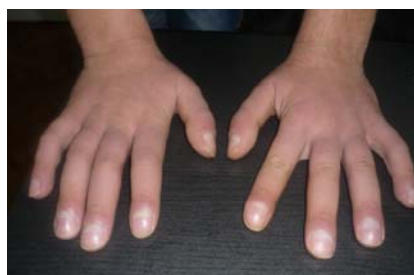

Fig. 2. Pachydermoperiostosis: thickening of the skin on dorsum of the hands

On examination of osteoarticular system finger clubbing, tibiotarsal joints swelling were noted. It should be noted that patient's mother and sister also presented with blepharoptosis but in the absence of other manifestations of PDP.

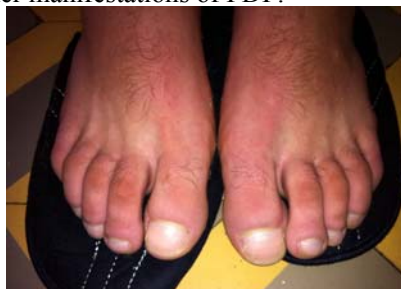

Fig. 3. Pachydermoperiostosis: thickening of the skin on feet

Hematological and biochemical tests and endocrine markers were within normal limits. CT scan of the cephalic extremity showed a normally-sized sella turcica, without intrasellar tumor, and thickened and folded skin of the scalp. Ultrasonography of the tibiotarsal joints showed bilateral edema of the perimalleolar superficial soft tissue and tendons. No intraarticular effusion or significant synovial proliferation was seen, but irregularities of the tibiotarsal bone surfaces, periostosis and calcifications were present.

Treatment consisted of Diclofenac gel 3 applications/day and long-acting Piroxicam 1 tablet/day for 10 days.

3. Discussion

HOA is a syndrome characterized by finger clubbing, periostitis and arthritis. PDP is the primary or idiopathic form of HOA in which, along with periostitis and finger clubbing, pachyderma represents the main characteristic. Besides these three major criteria PDP may be found a series of minor criteria: hyperhidrosis, arthralgia, joint collections, gastric ulcer, cutis verticis gyrata, blepharoptosis, edema, seborrhea, acne. Clinical suspicion of PDP is confirmed by radiography of the long bones.

In 1968 Friederich described a family case of HOA under the name of *hyperostosis of the entire skeleton* [4], and Pierre Marie described it as *osteoarthritis hypertrophiant pneumique* [7]. Touraine, Solente and Gole [17] are those who have individualized the PDP in 1935 as the primary form of HOA and called it *pachydermie plicaturee avec pachyperiostose des extremités* and also suggesting its classification into three forms: complete form including pachydermia, finger clubbing and periostitis; a fruste form with predominant pachydermia and minor skeletal modifications; and incomplete form in which pachydermia is missing.

In the pathophysiology of PDP the fibroblast is involved in fibrosis processes by increasing the production of collagen

fibers [8, 14]. PDP is a rare genetic syndrome, 25-38% of patients having a family history of the disease [9, 10]. Commonly, it is a disorder of autosomal dominant inheritance with variable expression and penetrance [9–12], but an autosomal recessive inheritance may also occur [3], [15]. PDP affects mostly men with a sex ratio of 9:1 [10].

The symptomatology of PDP is dominated by pachydermia which occurs mainly on the face and dorsal side of the hands and feet. In addition to skin thickening and deepening of facial skin folds (especially naso-labial folds), facial changes are also due to eyelids hypertrophy causing ptosis and giving the face an expression of despair. *Cutis verticis gyrata*, seborrhea of the face, palmoplantar hyperhidrosis, swelling of the calves with column-like appearance can also be found in the PDP. Hippocratic fingers, with thickening of the hands, feet and fingers occur during adolescence in 89% of patients [9, 10]. Joint collections (especially of the knees), arthritis, acro-osteolysis affecting the terminal phalanges of fingers and toes, or periostitis of the long bones are osteoarticular system changes encountered in PDP. Mental retardation in patients with PDP is moderate, rarely severe.

The clinical suspicion of PDP is confirmed by radiological examination that shows soft tissue swelling, irregular periosteal proliferation with cortical thickening of the long bones, metacarpals, metatarsals, phalanges and long bones epiphysis. Sometimes, calcifications of the musculotendinous insertions and Achilles tendon may be present [2, 16]. Bone scintigraphy shows a tracer accumulation in the area of affected joints and clubbed fingers [6].

The differential diagnosis should be made mainly with secondary HOA which occurs in various disorders including paraneoplastic syndrome, especially in men aged between 30 to 70 years. In the secondary form of HOA prevails painful

bone changes, the cutaneous changes being mild or absent. *Cutis verticis gyrata*, encountered in PDP, can be primary or secondary to diseases such as myxedema, hematodermia, neurofibromatosis, acromegaly. Psoriatic onychopachydermoperiostitis consists of association of osteoperiostitis with inflammation of the soft tissues of the distal phalanx and psoriatic onychopathy. Differential diagnosis should be completed with acromegaly in which there are changes in the skeleton of the face, as well as rheumatoid arthritis.

Treatment is mainly directed to alleviate rheumatologic manifestations. Nonsteroidal anti-inflammatory drugs may improve osteoarticular symptoms associated with PDP [18]. After two weeks of colchicine administration joint symptoms, folliculitis, and pachydermia are improved [11]. The improvement of rheumatologic symptom was observed after the intravenous administration of pamidronate 1 mg/kg [5]. Intra-articular corticosteroid injections improve the joint diseases. A dose of isotretinoin of 0.5 mg/kg/day resulted in an obvious improvement of cutaneous symptomatology (seborrhea, acne, folliculitis, pachydermia) [1]. Plastic surgery can be successfully used in the correction of facial wrinkles, excision of cutaneous folds or correction of blepharoptosis. Injections of botulinum toxin type A may improve facial wrinkles. Vagotomy can relieve pain and swelling of the joints and finger clubbing correction can be done surgically [11].

The particularity of the presented case is the presence of blepharoptosis in two other members of patient's family, suggesting that all the family members require a thorough physical examination for early diagnosis of incomplete or fruste forms of the disease.

References

1. Beauregard, S.: *Cutis verticis gyrata and pachydermoperiostosis. Several cases in a same family. Initial results of the*

- treatment of pachyderma with isotretinoin.* In: Ann Dermatol Venereol. (1994), Vol. 121, No. 2, p. 134-7.
2. Cantatore, F.P., Mancini, L., Ingrosso, A.M., Carrozzo, M.: *Pachydermoperiostosis: dermatological, neurological and radiological observations.* In: Clin Rheumatol. (1995), Vol. 14, No. 6, p. 705-7.
 3. Compton, R.F., Sandborn, W.J., Yang, H., Lindor, N.M., Tremaine, W.J., Davis, M.D., et al.: *A new syndrome of Crohn's disease and pachydermoperiostosis in a family.* In: Gastroenterology. (1997), Vol. 112, No. 1, p. 241-9.
 4. Friederich, N.: *Hyperostose des gesammten skelettes.* In: Virchows Arch. (1868), Vol. 43, p. 83-7.
 5. Guyot-Drouot, M.H., Solau-Gervais, E., Cortet, B., Deprez, X., Chastanet, P., Cotten, A., et al.: *Rheumatologic manifestations of pachydermoperiostosis and preliminary experience with bisphosphonates.* In: J Rheumatol. (2000), Vol. 27, No. 10, p. 2418-23.
 6. Jajic, I., Jajic, Z.: *The spectrum of skeletal and visceral abnormalities in 52 patients with primary hypertrophic osteoarthropathy.* In: Clin Exp Rheum. (1992), Vol. 10, p.73.
 7. Marie, P.: *De l'osteo-arthropathie hypertrophicante pneumique.* In: Rév Med. (1890), Vol. 10, p. 1-12.
 8. Martínez-Lavin, M.: *Pathogenesis of hypertrophic osteoarthropathy.* In: Clin Exp Rheumatol. (1992), Vol. 10, Suppl 7, p. 49-50.
 9. Martínez-Lavin, M., Pineda, C., Valdez, T., Cajigas, J.C., Weisman, M., Gerber, N., et al.: *Primary hypertrophic osteoarthropathy.* In: Semin Arthritis Rheum. (1988), Vol. 17, No. 3, p. 156-62.
 10. Matsui, Y., Nishii, Y., Maeda, M., et al.: *Pachydermoperiostosis - report of a case and review of 121 Japanese cases.* In: Nippon Hifuka Gakkai Zasshi. (1991), Vol. 101, No. 4, p. 461-7.
 11. Matucci-Cerinic, M., Ceruso, M., Lotti, T., Pignone, A., Jajic, I.: *The medical and surgical treatment of finger clubbing and hypertrophic osteoarthropathy. A blind study with colchicine and a surgical approach to finger clubbing reduction.* In: Clin Exp Rheumatol. (1992), Vol.10, Suppl 7, p. 67-70.
 12. Matucci-Cerinic, M., Lotti, T., Calvieri, S., Ghersetich, I., Sacerdoti, L., Teofoli, P., et al.: *The spectrum of dermatological symptoms of pachydermoperiostosis (primary hypertrophic osteoarthropathy): a genetic, cytogenetic and ultrastructural study.* In: Clin Exp Rheumatol. (1992), Vol. 10, Suppl 7, p. 45-8.
 13. Matucci-Cerinic, M., Lotti, T., Jajic, I., Pignone, A., Bussani, C., Cagnoni, M.: *The clinical spectrum of pachydermoperiostosis (primary hypertrophic osteoarthropathy).* In: Medicine (Baltimore). (1991), Vol. 70, No. 3, p. 208-14.
 14. Matucci-Cerinic, M., Sacerdoti, L., Perrone, C., et al.: *Pachydermoperiostosis (primary hypertrophic osteoarthropathy): in vitro evidence for abnormal fibroblast proliferation.* In: Clin Exp Rheumatol. (1992); Vol. 10, Suppl 7, p. 57-60.
 15. Sayli, U., Yetkin, H., Atik, O.S., Uluoglu, O., Bölükbaşı, S.: *Pachydermoperiostosis: a case report.* In: J Foot Ankle Surg. (1993), Vol. 32, No. 5, p. 480-3.
 16. Sega, A.M., Mackenzie, A.H.: *Hypertrophic osteoarthropathy: a ten-year retrospective analysis.* In: Semin Arthritis Rheum (1982), Vol. 12, p. 220-8.
 17. Touraine, A., Solente, G., Gole, L.: *Un syndrome osteodermopathique: la pachydermie plicaturee avec pachyperiostose des extremités.* In: Presse Med. (1935), Vol. 43, p. 1820-4.
 18. Schumacher, H.R. Jr.: *Hypertrophic osteoarthropathy: rheumatologic manifestations.* In: Clin Exp Rheumatol. (1992), Vol.10, Suppl 7, p. 35-40.