

INVASIVE ASPERGILLOSIS DURING INTENSIVE CYTOSTATIC THERAPY

D. VODA¹ D. SPIREA²

Abstract: *Whether it is a bacterial or a fungus infection, the medical literature shows a high risk of death due to infections during cytostatic therapy for hematologic diseases children. Invasive fungal infections are important risk factors for morbidity and mortality in cancer patients with neutropenia after de intensive cytostatic therapy. We are presenting a case report of invasive aspergillosis in the context of immunocompromised child after intensive chemotherapy for acute lymphoblastic leukemia.*

Key words: *acute lymphoblastic leukemia, invasive aspergillosis, immunosuppression chemotherapy.*

1. Introduction

Acute lymphoblastic leukemia represents a quarter of cancer cases diagnosed in childhood. The annual incidence in the US is 3.7 to 4.9 per 100 000 children aged <14 years with a peak incidence in children aged 2-5 years.[6] Acute complications of aggressive chemotherapy were the most frequent causes of death in patients with acute leukemia.

Empirical antimicrobial therapy is mandatory for all patients suffering from febrile neutropenia. Epidemiological studies show an increased incidence of fungal infections in patients with neutropenia associated with intensive chemotherapy, especially with *Aspergillus* species, *Candida non-albicans* species. They are an important cause of morbidity and mortality in haematological patients. [1], [2].

2. Case report

VB was brought into the hematology clinic in 11/01/2013 at the age of 9 years and 3 months for fever and spastic cough that started insidiously a week before, accompanied by fatigue and loss of appetite.

Noticeable in heredo-collateral history: father died in a car crash and his mother is a housewife aged 30 years and 8 months pregnant. He has another three siblings - all in good health. In his medical history he suffered a testicular trauma and a closed head injury at the age of 4 years by dropping from the cradle, no other hospital stays.

Physical examination on admission: mediocre general state, listless, sleepy, lacking appetite, pale skin, discreet bruising on right cheek and lower limbs, discreet lymphadenopathy in cervical, supraclavicular, and axillary regions with painless and non-adherent to the underlying

¹ *Transylvania* University of Brasov, Faculty of Medicine Braşov, Children Haematology Clinic from Children Clinical Hospital Braşov.

² Children Clinical Hospital Braşov.

plans, normal chest sounds, bilaterally symmetrical murmurs without any rales, rhythmic heart sounds, abdomen distended, painless to palpation, liver with inferior margins at 1.5 cm, impalpable spleen.

Highlighted through laboratory findings were leukocytosis (WBC = 73,700/mm³), lymphomonocytosis; with 70% lymphoblasts on peripheral smear and frequent schizocytes, pokilocytosis; marked microcytic anemia (RBC = 820,000/mm³, Hgb = 2.70 g/dl) and severe thrombocytopenia (PLT = 15,000/mm³) with marked inflammatory syndrome (ESR = 130 mm/1h). After bone marrow aspirate, immune-phenotyping and molecular biology we established acute lymphoblastic leukemia with B cell, intermediate risk.

Clinical course: the chemotherapy treatment was initiated according to ALL IC-BFM 2002 protocol. The bone marrow aspirate performed showed complete remission on day 33 showed <5% blasts in MO and severe neutropenia (WBC = 900 /ul- 22% neutrophils) after chemotherapy.

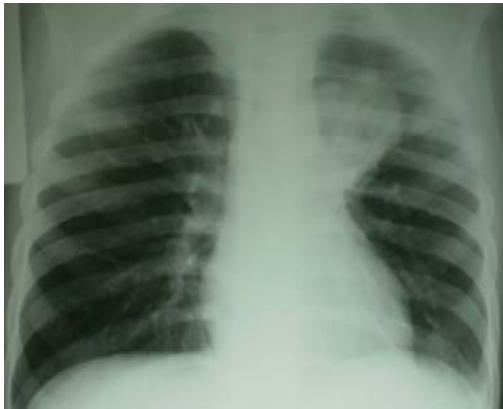

Fig. 1. *Chest radiography 11.12.2013*

On day 36 of protocol 1 (11.12) the chemotherapy treatment was stopped due to occurrence of severe neutropenia, fever, irritating cough in seizures, chest pain, and hemoptysis with blood clots.

Bacteriological investigations (11.12) - blood culture, urine culture, throat swab and nasal SLT were negative. This data were connected with the occurrence of alveolar opacities in the left upper lung lobe, evidenced by chest X-ray (fig. 1).




Fig. 2. *Scheme of antibiotics and antifungal drugs*

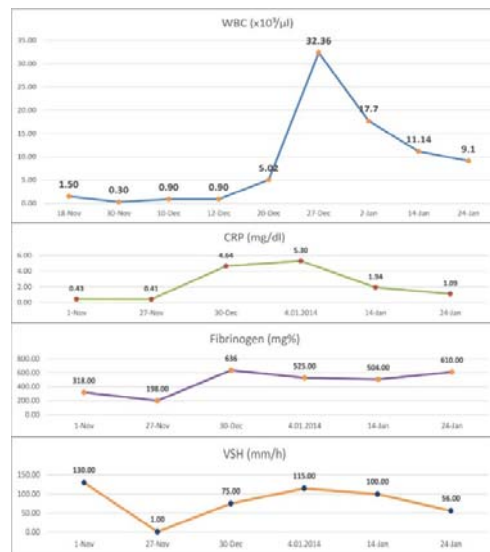


Fig. 3. *Evolution of WBC and inflammatory syndrome*

Based on these data he was diagnosed with lung abscess of the left superior lobe. Over the course of 45 days (December 11-January 24) he received broad-spectrum antibiotics such: Meropenem 21 days then Ceftamil (16 days), Vancomycin (21 days), Ciprinol (21 days), Biseptol (40 days), Voriconazole (5 days iv) then Itraconazole

(peros 8 weeks). From 3.01.2014 Clarithromycin po-15 days, 09-31.01-Clindamycin po-21 days (fig.2).

Progressively, we observed the slow growth of leukocytes from leukopenia post induction therapy to marked leukocytosis, microcytic anemia, thrombocytopenia and marked biological inflammatory syndrome (fig.3).

In **8.01.2014** pneumology consult was achieved for induced sputum examination negative and tuberculin skin test reaction for 2 u PPD- negative. Persistence of lung abscess at control chest X-ray performed in 6.01, after these antibiotic and antifungal regimens, entitled achieving a chest CT examination in 6.01(fig. 4)

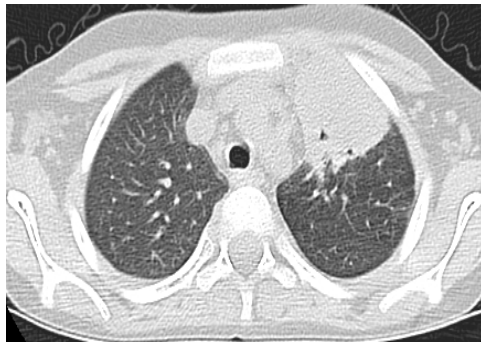

Fig. 4. *Chest CT 06.01.2014*

It was thus confirmed the diagnosis of left superior lung abscess of 42/29 mm and pleural foci condensation of right inferior lobe. Therefore a fungal infection was considered to be the cause of persistent lung abscess- pulmonary aspergilloma.

Clinical course until **24.01.2014**, under complex scheme antibiotic and antifungal therapy (IV / oral) was with remitted hemoptysis, intermittent fever and irritative cough. This period culminated with the occurrence in 24.01 of agonizing pain in the right lumbar region, radiation to the right leg and unable to sustain orthostatic position neither walking nor standing position. He received a palliative

care consult for pain therapy and received miorelaxants, Tramadol and NSAIDs, physiotherapy and massage slowly evolving favorably. The lab results showed leukocytosis (WBC=17,700/ mm³ of which 78% neutrophils) persistent biological inflammatory syndrome (ESR = 134 mm/h, CRP=5.30mg/dl, Fib=500mg %). Urinalysis reveals asymptomatic microscopic hematuria and pyuria.

Abdominal ultrasonography performed in this context in **4.02** highlights a replacement process located in the left renal parenchyma, rounded margins with long axis of 4 cm, hyper echoic center and hypo echogenic periphery, suggestive for renal abscess.

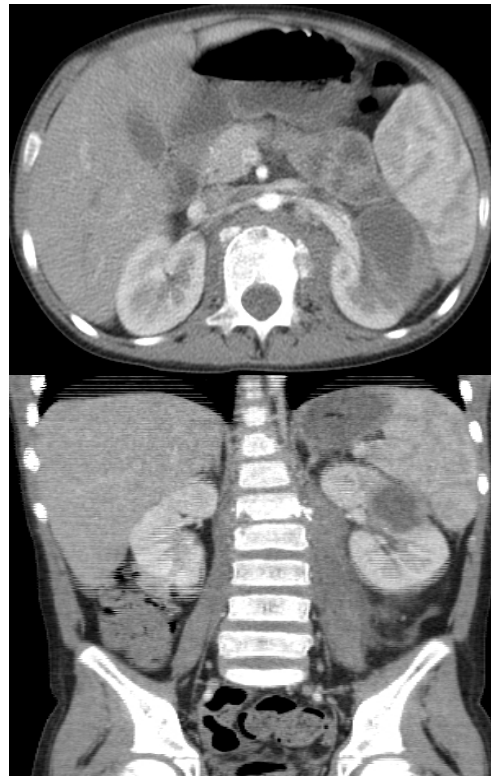


Fig. 5. *Chest and pelvis CT 07.02.2014*

In **7.02.2014** pelvis tomographic examination was performed, that revealed

a left renal abscess located in the cortical area of 41/26 mm, containing predominantly fluid and thick irregular walls. This examination also detected the narrowing of L1-L2 vertebral space and osteolytic and osteosclerotic reaction suggestive for spondylodiscitis lesions. Comparing with previous chest CT-scan examination (06.01) a decrease of about 8mm in the lung abscess was recorded after this two months of antibiotics and antifungal administration (oral Itraconazole) (Fig. 5).

A MRI examination was performed in **11.02.2014** which revealed the presence of the left renal abscess, fluid collections of paravertebral spaces suggestive for spondylodiscitis and the presence of a paravertebral abscess at the upper lumbar region, near the psoas muscle (fig. 6).

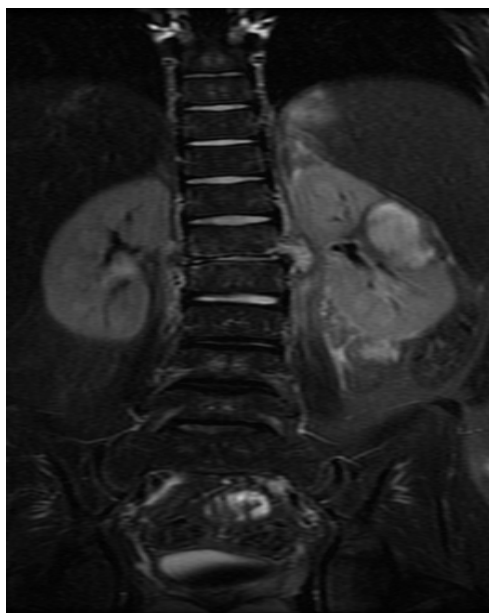


Fig. 6. Pelvis MRI 11.02.2014

As so, the systemic aspergillosis with pulmonary, kidney and spine involvement was considered and Ag *Aspergillus* (negative) and Anti-*Aspergillus* Antibodies (positive, titre 1/320) were harvested. Urine insemination and cultures for *Aspergillus* were performed, which all

came back negative. Another pneumology consult resumed with quateron test - negative. For another 29 days he received Voriconazole (iv 400 mg/day) and associated antibiotic therapy Ceftriaxone + Gentamicin (10 days) and Ciprinol.

At the end of Voriconazole iv treatment administrated, on **5.03.2014**, MRI imaging revealed enlargement of fluid paravertebral collections, also on the right side - the occurrence of contrast intakes at L1-L2 vertebral body and growth of the kidney abscess with perirenal extension touching the spleen also. Resistance to Voriconazole and the presence of other systemic fungal infection (mucormycosis) were considered. Therefore, iv treatment with Amphotericin B for 20 days (100mg/day) was initiated covering also the antibacterial germs and another 16 days along with Piperacillin/Tazobactam, 18 days Teicoplanine iv, 14 days oral Clarytromicin .

The clinical course was favorable with gradual remission of pain in the lumbar region, without fever, weight loss (3 kg in two months) and pyuria persistence.

Starting with **20.04.2014**, after completion of Amphotericin treatment, the abdominal ultrasound showed renal abscess in re-epithelialization and lymph nodes in the left renal hilum. Such, continuous oral Voriconazole therapy was initiated - from 22.04.2014 to 28.07.2014 (3 months) (Fig. 7).

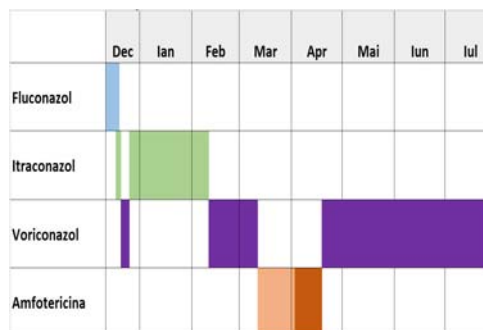


Fig. 7. Scheme of antifungal therapy

On **5.05.2014**, thorax and abdomen CT showed decrease of lung abscess from 36.5 mm to 21 mm, the left renal abscess and spondylodiscitis lesions of L1-L2 in remission (Fig. 8).

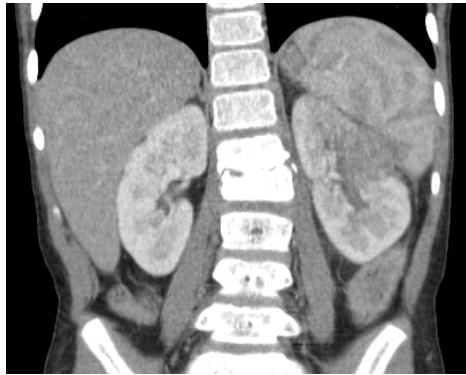

Fig. 8. *Pelvis CT 05.05.2014*

In **10.05.2014** bone marrow aspirate was performed which highlighted about 20% blasts in the bone marrow.

In **13.05.2014**, after about five months of chemotherapy interruption, resuming of the BFM- ALL 2002 Protocol I from day 36 with cyclophosphamide, cytosine arabinoside (16 administrations in four series of four administrations), and Methotrexate intrathecally and Purinethol (60mg/m²/day). During chemotherapy - good general condition, afebrile, hemodynamically and cardiopulmonary with no abnormalities detected. On day 60 of the 1st protocol, severe bone marrow aplasia after chemotherapy was observed, which required supportive treatment.

3. Discussions

Until 1960s acute lymphoblastic leukemia was considered deadly with short period of remission and death surveying in one year of the diagnosis. A major milestone occurred in the late 1960s when physicians began to treat occult central nervous system leukemia. Realizing that

central nervous system was present but not measurable, clinicians began to use cranial radiation and later intrathecal therapy prophylactically to prevent the spread of hidden disease. The 1970s witnessed the dramatic results of this therapy, as the first “cures” were recognized and survival rates improved dramatically to over 50%.

European investigators from Berlin, Frankfurt, and Munich (BFM) intensified the consolidation therapy by using higher doses and cycling multiple agents. This type of approach has resulted in a significant improvement in survival, especially for patients at high risk of failure [4].

Aggressive multiple agents chemotherapy is successful in inducing remission in about 85-90% of patients. Up to 5% of patients die of either infection or bleeding before a remission can be achieved [3]. The 5-year event-free survival varies considerably depending on risk category, from 95% (low risk) to 30-80% (very high risk), with infant leukemia having the worst outcomes. Acute complications may involve all organ systems and include the following: tumor lysis syndrome, renal failure, sepsis, bleeding thrombosis, typhilitis, neuropathy, encephalopathy, seizures [3].

Aspergillus spp is a filamentous fungus isolated from soil, plant debris, and indoor air environment. The spectrum of disease caused by *Aspergillus* is dependent on the health of the immune system. The ranges of illnesses individuals acquire are aspergilloma, allergic bronchopulmonary aspergillosis, invasive aspergillosis, sinusitis, otomycosis, ocular infections, CNS infection, osteomyelitis, cutaneous aspergillosis, endocarditis, urinary tract infection [5].

Risk factors for invasive aspergillosis include neutropenia, immunosuppressive therapy, high-dose systemic corticosteroids, AIDS, solid organ transplant and haematopoietic stem cell transplant. [4]

The incidence of fungal infections among patients who died during chemotherapy for acute leukemia at autopsy was 78.5%. The incidence of *Candida* and *Aspergillus* infections at autopsy was 40% and 60%, respectively. The mortality was 59% in the group of patients with fungal infection, and 43% in the group of patients without fungal infection [7].

As seen in our case report, the lungs are the most common site of primary invasive disease. The most common presenting symptoms in pediatric lung abscess are cough, fever, tachypnea, dyspnea, chest pain, vomiting, sputum production, weight loss and hemoptysis. The diagnosis of lung abscess is almost always made by imaging the lung first step radiographic film [4], [6].

Referring to our case report the radiological image interpreted as pulmonary abscess led us to take into consideration the bacteriological etiology (staphylococcal infection). Despite of clinical unfavorable evolution and with the persistence of lung abscess after all the antibacterial drugs received, we considered the possibility of fungal infection. This possibility was correlated with the re-installment of the hospital elevator which was located near the pediatric hematooncology department with a possibility of iatrogenic aspergillosis. Our presumption was confirmed by elevated serum levels of *Aspergillus* antibodies.

In the next weeks, the patient presented the expansion of fungal infection touching also the renal parenchyma and lumbar spine which entitled us to establish the final diagnosis of systemic aspergillosis.

This required long-term antifungal therapy during approximately seven months with alternating with intravenous and oral drugs.

The patient continued the chemotherapy protocol with complete remission and periods of bone marrow aplasia without any clinical or laboratory signs of fungal infection.

4. Conclusion

We are presented a case report of iatrogenic invasive aspergillosis (pulmonary, kidney, vertebral disc) in the context of immunocompromised child after intensive chemotherapy induction for acute lymphoblastic leukemia, with long antifungal therapy (seven month) and interruption of chemotherapy.

References

1. Freifeld A.G., Bow, E.J.: *Clinical Practice Guideline for the Use of Antimicrobial Agents in Neutropenic Patients with Cancer: 2010 Update by the Infectious Diseases Society of America*. In: *Clinical Practice Guideline CID 2011:52*, p. 56-e93.
2. Groll, A.H., Walsh, T.J.: *Invasive Fungal Infections in the Neutropenic Cancer Patient: Current Approaches and Future Strategies*. In: *Infect Med.*, 2002; 19(7) p. 1-7.
3. Kliegman, R.M., Bonita, Stanton Nelson, F.:- *Textbook of Pediatric* 19th Edition. Elsevier Philadelphia USA 2011, p1058-1062; p 1732-1737.
4. Seibel, N.L.: *Acute lymphoblastic Leukemia: An Historical Perspective* In: *ASH Education Book*, January 2008 no 1 p. 365.
5. Shah-Hosseini, N., Khabiri, A., Bagheri, F.: *The spectrum of diseases caused by Aspergillus fumigatus*. In: *Iran J Clin Infect Dis* 2011 Vol. 6, No. 3, p. 136-141.
6. Zmeili, O.S., Soubani, A.O.: *Pulmonary aspergillosis: a clinical update*. In: *Q J Med* 2007 Detroit USA; 100:317-334.
7. Zupanić-Krmek, D. Nemet, D., et al.: *Risk factors for invasive fungal infections during intensive chemotherapy of acute leukemia retrospective study*. In: *Acta Med Croatia* 2004; 58(4):275-8.