

# FULMINANT HEPATIC FAILURE AS AN ONSET OF SECONDARY HEMOPHAGOCYTTIC LYMPHOHISTIOCYTOSIS IN CHILD - CASE REPORT

D. VODA<sup>1</sup> C. BUTA<sup>2</sup> S.GULEA<sup>3</sup>

**Abstract:** Hemophagocytic lymphohistiocytosis (HLH) is a potentially fatal syndrome that occurs as a consequence of a pathological activation of the body's immune system which further generates a severe inflammatory response. Because HLH's clinical framework can be varied and because HLH is a rare disease, diagnosing it can prove to be quite challenging. We will present the clinical case of a child known with Nephrotic Syndrome, corticosteroid-dependent, who develops HLH, secondary to an Epstein Barr viral infection, with an onset that presents itself as a fulminant hepatic failure.

**Key words:** Hemophagocytic lymphohistiocytosis, secondary hemophagocytic syndrome, Epstein Barr Virus.

## 1. Introduction

Hemophagocytic lympho-histiocytosis (HLH) also known as hemophagocytic activation syndrome is a biological and clinical entity characterized by excessive and uncontrolled activation and proliferation of macrophages and T cells, hemophagocytosis, high levels of pro-inflammatory cytokines in the blood leading to a progressive dysfunction of all body functions [1]. HLH can occur in two forms: primary (genetic) caused by certain genetic mutations of the protein that takes

part in the structure of the cytolytic cells (NK-cells and cytotoxic T cells), or secondary (acquired) after a viral, bacterial, parasitic infection, in association with immunosuppressive treatment, malignancies, rheumatic or metabolic disorders [2]. Clinical criteria for a diagnosis: 1) prolonged fever > 38.5°C, 2) splenomegaly, 3) cytopenia (bicytopenia or pancytopenia: hemoglobin <9 g/dL), platelets < 100 x 10<sup>3</sup>/mL; neutrophils < 1 x 10<sup>3</sup> /mL), 4) hypertriglyceridemia (>265 mg/dL) or hypofibrinogenemia (<150 mg/dL), 5) the presence of hemophagocytosis

---

<sup>1</sup> Faculty of Medicine Brasov, *Transilvania* University of Brasov, Children Haematology Clinic from Children Clinical Hospital Brasov.

<sup>2</sup> Children Clinical Hospital Brasov.

<sup>3</sup> Faculty of Medicine Brasov, *Transilvania* University of Brasov.

in the bone marrow, spleen, lymph nodes or liver, 6) a decrease or the absence of activity of NK cells, 7) ferritin > 500 ng/mL, 8) increase of sCD25, 9) hepatic cytolysis tests, 10) hemophagocytic or hyponatremia [3], [4].

## 2. Case presentation

Child E.A.N, aged 9, male, diagnosed with Nephrotic Syndrome at the age of 2 years and 8 months, has relapsed several times (12 relapses), in treatment with Corticosteroids, hospitalized at the Clinical Children's Hospital Brasov between 22nd of May - 20th of June 2014 because of a new relapse with the following symptoms: edema in the eyelid region, pretibial region, scrotum, posterior area of the hands and oliguria.

Clinical examination at hospital admission: average general state, no fever, weight - 33 kg, height - 129 cm, BMI - 21,56 kg/m<sup>2</sup>, infiltration of the skin as a result of Corticosteroid therapy, edema in the eyelid region, pretibial region, scrotum, posterior area of the hands, dry lips, light congestion of the pharynx, hepatosplenomegaly absent, stable, conscious state retained, pale skin, cardiac and respiratory infiltration, heart rate - 80 bpm, blood pressure- 100/60 mm Hg, light bloating of the abdomen, painless and depressible abdomen, bowel movements present, oliguria, spatial and temporal orientation present, no signs of meningeal irritation. Paraclinical investigations performed during hospital admission revealed leukocytosis with neutrophilia, inflammatory syndrome present, hypoproteinemia, proteins present in urine, dyslipidemia, serum ionogram, hepatic tests and renal test in normal range. The patient received Corticosteroid treatment, initially IV and later orally, with a

progressive decrease of doses, in association with Albumin, Furosemide IV after the administration of Albumin, gastric protectors, Calcium, Vitamin D, KCl 5% solution orally, with favorable evolution, remission of the generalized edema, normal diuresis, normal blood pressure, remission of the proteinuria, from 30,8 g/24 h on 23rd of May 2014, to 0.08 g/24 h on the 6th of June 2014, increase of proteinemia from 4,4 g/dL on the 22nd of May 2014 to 6,3 g/dL on the 5th of June 2014.

On the 6th of May 2014 the patient experiences diarrhea, abdominal pain and food vomiting and develops an erythematous maculopapular rash in the scalp area, thoracic and abdominal areas, with non pruritical traits (fig.1).

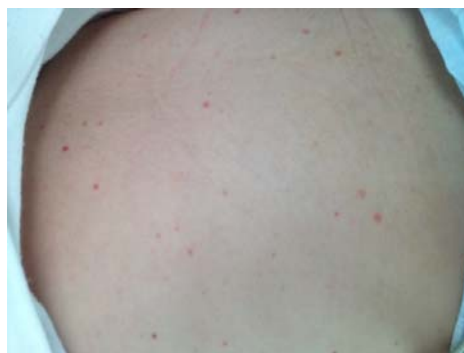

Fig. 1. *Erythematous maculopapular rash*

The next day, the patient's general condition is altered and the patient suffers from generalized tonic-clonic convulsions that last approximately 3 minutes with limited eyesight and stertorous breathing, post critical somnolence (glycemia, ionogram, oxygen saturation, blood pressure in normal range) - for these clinical manifestations the patient receives Desitin intrarectally (2 administrations) and after that, Phenytoin

IV after which the convulsions disappear and the patient is transferred to the hospital's ICU.

At the ICU the patient continues to suffer convulsions on the right side of the body and receives a second dose of Phenytoin IV, Corticosteroid therapy, Mannitol, gastric protectors, antibiotics therapy. A new clinical examination reveals an extension of the erythematous maculopapular elements and vesicles with hemorrhagic aspect for which the patient receives immunotherapy IV and anti viral treatment (fig.2).

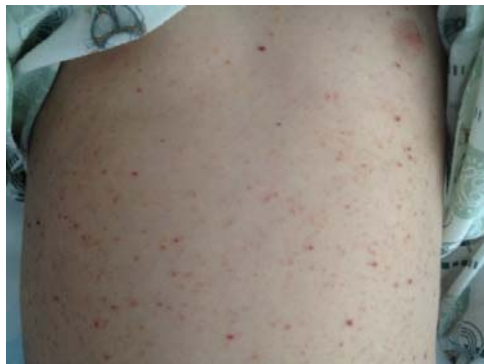

Fig. 2. *Polimorphic eruption with pruritical traits, vesicles with hemorrhagic aspect*

On the 9th of June, the patient is neurologically examined: no clinical signs of focal lesion, Babinski test negative on both sides, spatial and temporal orientation present, he is scheduled for an emergency cranial CT which suggests a possible Encephalitis, Meningo-Encephalitis, which should be evaluated in a clinical context, continuing the treatment with Phenytoin – IV slow and Phenobarbital IM, if needed. During the same day, a lumbar puncture

was performed - CSF with clear aspect, colorless, normal pressure with 5 leukocytes/mm<sup>3</sup>, Pandy Reaction negative, Albumin 0,26 g %, Glucose 0,82 g %, Chlorides 6,6 g%, paraclinical investigations were also performed and revealed high leukocytosis with neutrophilia evaluated as a secondary effect of the Corticosteroid therapy, light thrombocytopenia, severe hepatocytolysis syndrome with a longer prothrombin time for which the patient received fresh frozen plasma, Crioprecipitate, Fitomenadion, Aspatofort. During evolution, on the 8th of June, the patient manifested fever 38°C and tonical-clinical convulsions, gastric reflux with fresh blood on the nasogastric tube, increased values of the BP (140/100 mmHg) for which the patient received Enap.

On the 10th of June, the patient is in an altered state but with retained consciousness, the patient responds to verbal and painful stimulation, no sign of convulsions since the 9th of June, no fever but an extension of the vesicular eruption with hemorrhagic aspect can be observed, hematoma in the lumbar puncture area, cardio vascular and respiratory systems balanced, liver at 1 cm below the costal margin, impalpable spleen, diuresis present, liquid with coffee aspect coming out the nasogastric tube. Paraclinical investigations show an increase of the hepatic enzymes (AST = 6126, ALT = 4806, LDH = 20336), low fibrinogen (124 mg%), an increase of ammonia levels in the blood, D dimers present, high Procalcitonin (fig 3).

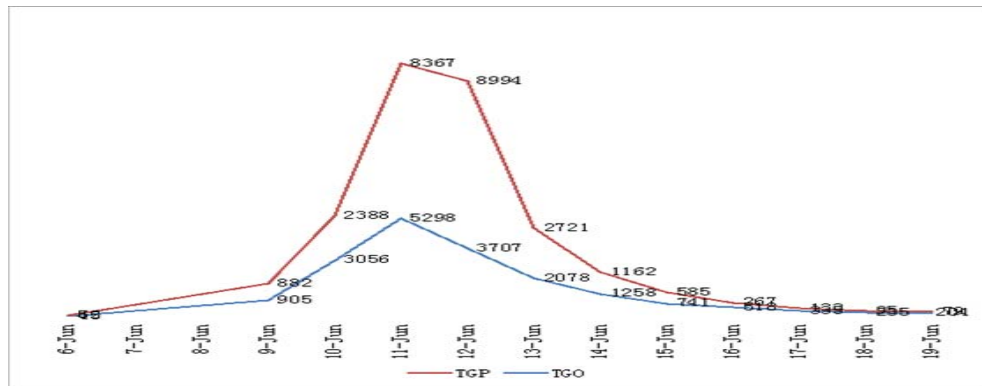


Fig 3. Evolution of transaminases during hospitalization

An abdominal ultrasound examination was performed - no changes of the abdominal organs. Epstein Barr and Cytomegalovirus serological tests were performed (increased titer for IgG, IgM negative) and Antibodies anti Varicella Zoster Virus (IgG positive, IgM negative). Acyclovir IV was administered. The differential diagnoses was made with the following: Varicella - severe form in an immune suppressed child (who received prolonged doses of Cortisone, who came in contact with affected persons in school before the 22nd of May, the situation wasn't reported by the child's mother at hospital admission), Meningo-encephalitis in the context of Varicella (suggested by CT aspect, but the lumbar puncture was normal), Reye Syndrome (Encephalopathy in association with severe hepatic dysfunction).

The patient was examined at the Infectious Diseases Hospital in Brasov and the Varicella suspicion was excluded: initially based on the clinical aspect of the eruption and afterwards based on the viral serological tests (negative Antibody anti Varicella Zoster Virus IgM). The suspicion of Hepatitis with A, B, C Virus was also excluded, as well as the case with the Herpes Simplex viral infection (negative serological tests for both possible

diagnoses). Reactivation of the Epstein Barr viral infection was discussed (increased titer of IgG- VCA) - Viral EBV DNA was collected (positive result - PCR method). Antibiotics treatment was administered and the previous therapeutic scheme was continued: Corticosteroid therapy - a progressive decrease of the doses (eventually, the Corticosteroid therapy was halted), antiviral therapy, gastric protectors, Mannitol, Phenytoin, Fitomenadion, Immunoglobulins, Neomycin, Lactulose on the nasogastric tube (increased values of the ammonia in blood), Aspatofort IV, Arginine, erythrocyte transfusion therapy, fresh frozen plasma, Crioprecipitate (15 units), platelet mass (11 units), perfusion with Glucose 10%, electrolytes, Vitamin B and aminohepa 10%, Furosemide IV.

In evolution (between 9th of June- 17th of June), the patient displayed altered general state, daily fever (38°C-39.6°C) which was difficult to decrease by physical means and the use of drugs, somnolence (but still cooperative), episodes of visual hallucinations (fever linked), the extension of the erythematous maculopapular eruption with hemorrhagic aspect (Fig 2), bleedings and ecchymosis on the venous puncture spots. The peripheral vascular access was compromised and a central

venous catheter (CVC) was necessary starting with the 11th of June and also administration of prothrombine complex IV. The abdomen was slim and depressible, liver at 2 cm below the costal margin, impalpable spleen, fresh blood in large quantity collected from the upper gastrointestinal tract (500 ml/24 h) with a progressive decrease of the digestive bleeding and stools with melena aspect, until the 15th of June. During this period, the Oxygen saturation was normal, but the

patient displayed tachycardia (especially during the fever episodes), high blood pressure values (systolic BP 130-110 mm Hg, diastolic BP - 70-107 mm Hg), diuresis present with hypochromic urine aspect, diuresis/24h = 3500 ml (balanced liquid intake - liquid excretion). The hepatic cytolysis test values were situated at a high level, fibrinogen levels, the platelets and the hemoglobin levels decreased, the coagulation tests were modified, ferritin was increased (Fig 4).

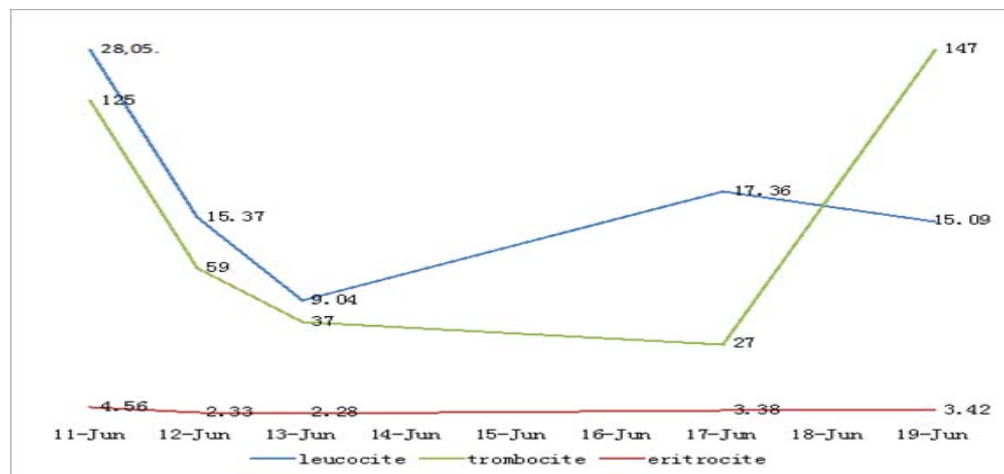


Fig. 4. *The dynamics of the CBC*

Beginning with the 17th of June 2014, the patient's state improves, no fever present, no new pathological elements on the skin, the present elements remained stationary, scleral jaundice, no externalized bleedings, no epistaxis, no blood collected from the upper gastrointestinal tract, spontaneous breathing, vesicular murmur present on both sides, no rales, slim and depressible abdomen, liver at 2 cm below the costal margin, impalpable spleen, diuresis present with the increase of proteinuria on the 17th

of June (2,95 g/24h), no edemas, a slight decrease of the BP values, heart rate = 86-122 bpm. Progressive increase of hemoglobin values, an increase of platelets was also observed, hepatocytolysis syndrome and coagulation abnormalities in remission, an increase of the triglycerides, amilasemia, a serious increase of the ferritin (7219 ng/ml) and low values of the fibrinogen (on the 19th of June- 150 mg/dl), with renal function retained (Fig 5).

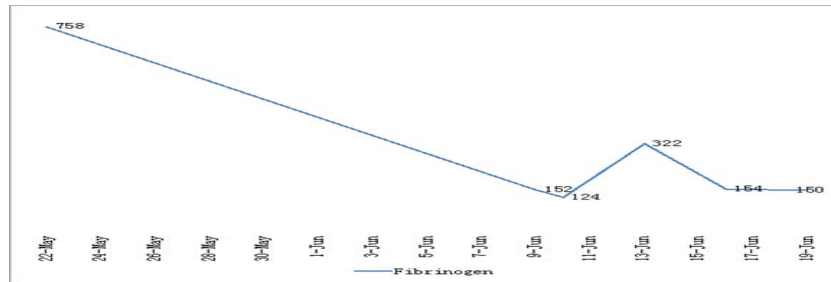


Fig. 5. *The dynamics of the fibrinogen values*

On the 20th of June 2014, because the general state of the patient has improved, the child is transferred to the Pediatric Nephrology Department of the Fundeni Pediatrics Clinic in Bucharest, for a detailed clinical and biological evaluation and for preparing a therapeutic scheme for the Nephrotic Syndrome. The Pediatric Clinic Fundeni confirms the secondary Hemophagocytic lymphohistiocytosis diagnosis, on the grounds of hematologic abnormalities (decreased hemoglobin, thrombocytopenia), increased ferritin 1000 ng/dL, increased triglycerides = 230 mg/dL and coagulation abnormalities, fibrinogen = 137 mg/dL. During hospitalization, no signs of upper gastrointestinal tract bleedings, no edema and normal blood pressure values. The patient receives Corticosteroid therapy (initially IV and then orally) associated with immunosuppressive treatment (Cyclosporine), supportive treatment (fresh frozen plasma, perfusion for electrolyte balancing, gastric and hepatic protectors), anti hypertension therapy and antibiotic therapy. The patient's evolution was favorable under this treatment, with remission of the hemophagocytic activation syndrome, improvement of the Nephrotic Syndrome symptoms and improvement of coagulation abnormalities. The patient is thus discharged from the hospital with good general state, no fever, clean skin and mucosae, cardiac and respiratory systems well balanced,

biological tests significantly improved and with a prescription for continuing the Corticosteroid therapy, anti hypertension therapy and Cyclosporine administration.

On the 21st of July 2014, the child presents at the Clinical Children's Hospital in Brasov for a biological and clinical reevaluation. Clinical examination at admission in the hospital: good general state, W = 33,5 kg, no fever, infiltration of the skin as a result of Corticosteroid therapy, no edema, digestive, cardiac and respiratory systems well balanced. Heart rate = 78 bpm, BP = 109/81 mm Hg, liver near the costal margin, inferior pole of the spleen palpable in deep breath. Notable paraclinical test results: CBC with leukocytosis and thrombocytosis evaluated as effects of the chronic Corticosteroid therapy, hemoglobin in normal range, inflammatory syndrome absent, renal tests, proteinuria, hepatic tests with normal results (TGO at the upper normal limit), serum ferritin in normal range. Further medical advice: continuing the Corticosteroid therapy, immunosuppressive therapy, anti hypertension therapy, gastric protectors in the same therapeutic scheme, with reevaluation scheduled in 2 months or immediately in case of a relapse of the Nephrotic Syndrome, with edema and oliguria signs.

### 3. Discussions

Before beginning treatment the most important aspect is determining the type of HLH (primary or secondary). Secondary HLH (acquired) is associated with severe viral infections (most frequently with the EBV) or with long term immunosuppressive treatment, malignancies, autoimmune syndromes, metabolic syndromes. In our case HLH was associated with chronic immunosuppressive treatment, which created the conditions for a reactivation of a prior EBV infection which expressed in the form of a fulminant hepatic failure. The HLH diagnosis was sustained on hematological changes (decreased hemoglobin = 6 g/dL, thrombocytopenia =  $27 \times 10^3$ /mL), hypofibrinogenemia = 124 mg% and on the hepatic cytolysis tests together with the increase of the triglycerides = 345 mg/dL, increased serum ferritin = 7219 ng/mL, coagulation abnormalities in the context of the reactivation of the infection with the Epstein Barr virus. The evolution of HLH, especially the HLH associated with the EBV infection is severe and potentially fatal given the fact that there are no specific therapeutic protocols. The fatal complications of HLH are: hemorrhagic diatheses, infections and multiple organ failure [5]. The recommended treatment of secondary HLH is: treating the initial disorder, Corticosteroid therapy, immunoglobulins IV and supportive treatment. According to scientific sources, treating the HLH secondary to a viral infection with the EBV the recommended treatment includes immunoglobulins administered iv, Corticosteroid therapy IV, new generation of antiviral drugs (Ribavirin) or immunosuppressive treatment (initially Etoposide, when the patient has stable BP, renal and hepatic functions Cyclosporine A can also be administered) and Methotrexate

intrathecal for the patients with neurological symptoms and anomalies of the CSF [6], [7]. If fever reoccurs after administration of treatment it can be considered that there was a reactivation of the HLH or an opportunistic infection developed - in this case a broad-spectrum antibiotic therapy can be introduced. There are certain cases of HLH secondary to an infection with EBV that are resistant to the treatment mentioned above which require hematopoietic stem cells transplant [8], [9].

### 4. Conclusions

In this case, a patient with Nephrotic Syndrome in treatment with Corticosteroid therapy which induces chronic immunosuppressant effects, suffers a reactivation of an infection with Epstein Barr Virus which determines a pathological activation of the macrophages and of the immune system which further generates an exaggerated inflammatory response of the body. These conditions are responsible for developing a fulminant hepatic failure which, together with the modified lab tests, can guide us towards a diagnosis of the HLH.

### References

1. Cacopardo, B., Nunnari, G., Mughini M. T. et al.: *Fatal hepatitis during Epstein- Barr virus reactivation*. European review for medical and pharmacological sciences. Catania, Italy, 2003, p. 107-109.
2. Fan, D. Z., Qian, X. Q., Yu, H. G.: *Pancytopenia as an early indicator for Steven-Johnson syndrome complicated with hemophagocytic lymphohistiocytosis: a case report*. In: BMC Pediatrics, 2014, 14:38, <http://www.biomedcentral.com/1471-2431/14/38>.

3. Filipovich, H. A.: *Hemophagocytic lymphohistiocytosis (HLH) and related disorders*. In: Hematology, Cincinnati, OH, 2009, p 127-131.
4. Gulen, H., Aslan, S., Simsek, A.: *Fulminan hepatik yetmezlikte basvuran hemofagositik sendromlu bir olgu (A case of hemophagocytic syndrome that presented as fulminant hepatic failure)*. In: Ege Journal of Medicine, Manisa, Türkiye, 2011, p. 193-196.
5. Jabado, N., McCusker, C., Saint Basile, G.: *Pediatric Hemophagocytic Syndromes: A Diagnostic and Therapeutic Challenge*. In: Allergy, Asthma, and Clinical Immunology, 2005, vol 1, nr 4, p. 142-161.
6. Jordan, B. M., Allen, C. E., Weitzman, S., et al.: *How I treat hemophagocytic lymphohistiocytosis*. In: Blood Journal, Toronto, ON, 2011, p. 4041- 4053;
7. Kleyenberg, L. R., Gary, J. S.: *Secondary Hemophagocytic Lymphohistiocytosis in adults: an update on diagnosis and Therapy*. In: Clinical Advances in Hematology & Oncology, Los Angeles, California, 2012, p. 727-732.
8. Srichaikul, T., Punyagupta, S., Mongkolsritrakul, W., et al.: *Hemophagocytic Syndrome with Fulminant Multi-organ Failure after Tasting Raw Monkfish Liver: The Patient Survived by Immunomodulators and Plasma Exchange Therapy: a case report*. In: J Hematol Transfus Med, Vichaiyut, Thailand, 2011, p. 261-266.
9. Weitzman, S.: *Approach to Hemophagocytic Syndromes*. In: Hematology, Toronto, ON, 2011, p. 178-183.