

FEMORAL NECK FRACTURES

C. COSTACHE¹ D. COSTACHE¹

Abstract: *We have conducted a retrospective study on a group of 124 patients who had been hospitalized and operated on in the Department of Orthopaedics of the Clinic Emergency Hospital of Braşov County in 2013. The parameters we focused on were the following: the sex and age of the patients, the type of fracture, the surface of the femur where the fracture occurred, and the type of surgery performed.*

Key words: *fracture, femoral neck, arthroplasty.*

1. Introduction

The femur is the longest bone of the body which, by itself, forms the skeleton of the thigh. It is made up of the body, the upper extremity and the lower extremity. The upper extremity (proximal extremity) is, in its turn, made up of a head, a neck and two shafts called ‘the greater’ and ‘the lesser’ trochanter. The upper extremity is connected to the body by means of a surgical neck.

The femoral neck is a strong pyramidal process of bone, which is flattened from before backward and which connects the head to the rest of the bone. Through it the weight of the human body is transmitted from the hip bone (pelvis) to the free inferior limb.

The direction of the conveyed forces requires a high resistance on behalf of the neck, which explains its extremely complex trabecular architecture, formed by a system of grooves.

After the age of 50, this trabecular system starts weakening, the medullary cavity continuing in the upper extremity.

The weight of the body and the bone resorption favour neck fractures.

2. Objectives

The study was carried out in 2013, on a group of 124 patients who had been operated on in the Department of Orthopaedics of the Clinical Emergency Hospital of Braşov County.

The parameters we focused on were the following: the sex and age of the patients, the type of fracture, the surface of the femur where the fracture occurred, and the type of surgery performed.

3. Material and Methods

The bone substance is displayed in two important trabecular systems, one being situated at the level of the femur neck, the other at the level of the trochantric crest.

a) The trabecular system at the level of the femur neck is made up of two ‘fans’: Delbet’s sustaining ‘fan’ and Duhamel’s supporting one. The intersection of these ‘fans’ in the middle of the femur neck brings about the central hard core of the

¹ Faculty of Medicine, *Transilvania* University of Braşov.

head and constitutes a solid supporting point for the metallic devices employed in achieving various types of osteosynthesis performed today. Actually, the femur neck represents the most resistant part of the proximal extremity of the femur and it maintains this resistance, which decreases among elderly people.

b) The second trabecular system is situated at the level of **the trochanteric area** and it represents the second high resistance area.

It is situated at the junction of the femoral neck with the great trochanter and it is formed by the 'sustaining arch' with its two pillars which are supported on the internal, respectively external cortical blade.

The piles of the arch maintain this zone compact; from here the Delbet's arch bolt goes down.

Between the two resistance systems there is a weak area (Ward's triangle/area), which is basically the place where most femoral neck fractures occur.

The fractures of the femoral neck represent approximately 7% of the total of fractures.

They are mainly encountered among elderly women who are affected by both the senile and by the post-climacteric endocrine osteoporosis [3].

There are a number of classifications of the femoral neck fractures, as illustrated below:

3.1. Delbet's (anatomic) classification

Delbet classifies neck fractures into: sub-capital, mediocervical and basicervical fractures. Only the first two types are considered to be real femoral neck fractures. The basicervical fractures present a number of similarities with the trochanteric fractures.

3.2. Bohler's (pathogenic) classification

This classification is based on the ways the fracture occurs:

- 1) Abduction fractures (fractures in cox-valga) resulting from an impact on the posterior-superior area. It represents about 15 % of the total of femoral neck fractures.
- 2) Adduction fractures (fractures in cox-vara), with displacement. They represent 85% of the total of fractures of the femur neck.

3.3. Pauwels' (bio-mechanical) classification

Based on the angle of the fracture's trajectory with the horizontal line, shows that those fractures that have a more horizontal trajectory will present a higher interfragmentary strain in the fracture focal point, which will favour consolidation.

As the fracture trajectory comes close to the vertical line, the compression forces in the focal point are replaced by shearing and traction forces that lead to non-consolidation and pseudo-arthrosis.

- 1) First degree fractures: the angle formed by the fracture trajectory and the horizontal line is smaller than 30° , a situation that has good chances of consolidation.
- 2) Second degree fractures: the angle is between 30° and 50° , the shearing forces are important, sometimes leading to displacements and pseudo-arthrosis.
- 3) Third degree fractures: the angle between the fracture trajectory and the horizontal line is greater than 50° . This type of fracture almost always develops into pseudo-arthrosis.

3.4. Garden's classification

Is based on the neck's trabecular system. The author classifies fractures into 4 types:

1) Type I covers incomplete fractures and abduction fractures, in the *coxa valga* in Bohler's classification.

The bone columns of the femoral neck are inclined and oriented in a slight valgus. They usually have a favourable recovery and can be treated orthopedically.

2) Type II covers complete fractures, without displacement.

3) Type III – complete fractures with partial displacement. The posterior synovial and the pectinofoveal fold (with the blood vessels that go through it) keep together the fractured fragments, conferring them certain stability. Such fractures usually heal nicely.

4) Type IV – complete fractures with total displacement. The synovial of the femoral neck is broken; it takes a long time to heal and presents a high degree of instability.

The treatment of the femoral neck fractures is basically surgical. Many authors state that femoral neck fractures are the hardest to treat of all. It has been shown that the rate of death, even among very old patients, is smaller in the case of operated patients as compared to those that have not been operated on.

Displaced fractures (Gardner's types III and IV) should be treated by means of osteosynthesis as soon as possible, right when the patient comes to the emergency room, if possible [2].

3.5. Surgical treatment

I. Osteosynthesis with screws in femoral neck fractures

This procedure is recommended in the case of non-displaced intracapsular fractures of the femoral neck (Garden's type I and II) and in the case of displaced femoral neck fractures (Garden's type III and IV) that can be reduced by means of orthopaedic manoeuvres. In order for the intervention to be successful, the patient's

bone stock should be of good quality and his/her age should not exceed 70. It is of major importance that the fracture should be reduced and fixed within 24 hours. The longer the time between the moment the fracture occurred and its reduction, the higher the chances of aseptic necrosis of the femoral neck.

The anatomic reduction of the fracture focal point is an essential condition for consolidation. This should be performed on the orthopaedic table, by means of external manoeuvres, under Roentgen-TV control/surveillance.

Osteosynthesis should be performed, if possible, without arthrotomy, by introducing under x-ray control 2 transtrochanteric-cervico-capital screws. The screws can be placed in parallel or in 'triangulation' so as to fix the fragments as well as possible and to prevent rotation tendencies of the proximal fragment [6].

The patient could start moving 2 or 3 weeks after surgery, using crutches. She/he is not allowed to walk on the respective limb sooner than 4 months after surgery.

It is advisable that about 2 months after the surgical intervention the patient should undergo a scintigraphic check up of the hip; if there are signs of consolidation, sustenance by means of screws will be maintained.

If there are no signs of consolidation, we will replace the femoral neck with a bipolar prosthesis or, in extreme cases, with a cervico-cephalic prosthesis of the Moore type.

In the well selected cases, osteosynthesis by means of screws in the femoral neck fractures is an option that allows the preservation of the femoral neck and the resumption of the hip functions [8].

The global rate of failure remains, nevertheless, rather high and when it comes to choosing between osteosynthesis and arthroplasty, it is of major importance to know the patient well in order to see

whether s/he is capable or strictly obeying the doctor's indications for the post-surgical period.

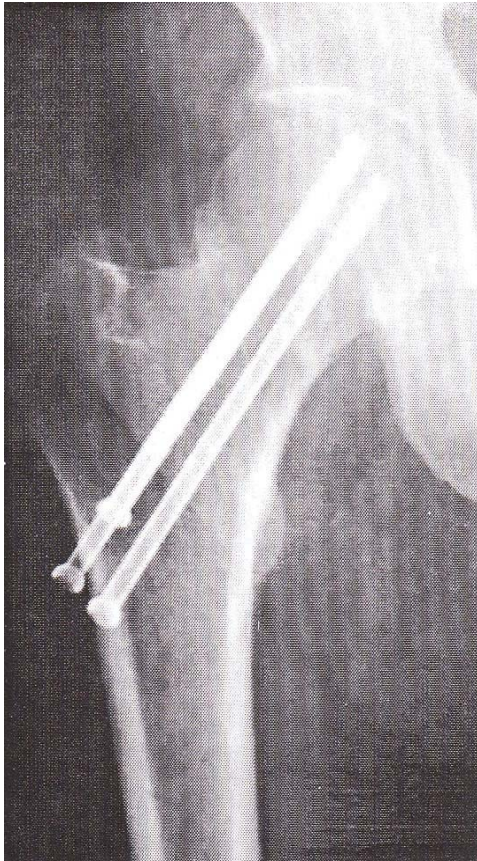

Fig.1. *Osteosynthesis with screws*

II. Hemiarthroplasty in femoral neck fractures

In the case of very old patients suffering from severe osteoporosis, these prostheses should be cemented to prevent 'indentation' in the femur (the Thomson prosthesis).

The advantages of hemiarthroplasty with metallic endoprosthesis of the Moore type are the following:

- it enables the fast recovery of the joint and of the patient who could start

Although the technique seems easy, the perfectly parallel placement of the screws in the neck axis requires a certain degree of experience [3].

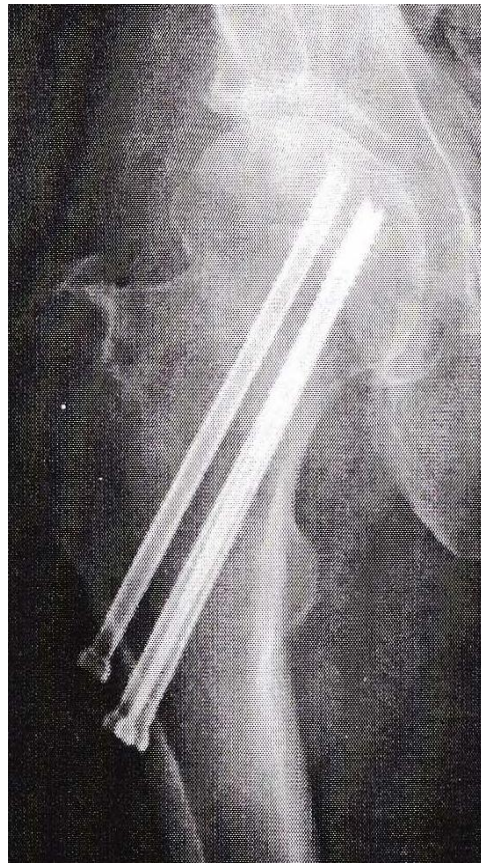


Fig. 2. *Osteosynthesis with screws*

walking after 3 or 4 weeks;

- it shortens the period spent in hospital and the convalescence and facilitates the patient's recovery;

- it avoids the risk of pseudo-arthritis and of aseptic necrosis of the femoral neck;

- it 'solves' the neck fractures that cannot be reduced or fixed solidly;

- it is one of the acceptable solutions for the fractures of pathological bones (especially in neoplastic metastases);

- it is an extreme solution in the cases in which the metallic device has deteriorated and the fragments have undergone secondary displacement;

- by making the pain disappear, it has an extremely positive psychic effect on the patient; at the same time, it makes the activity of tending the patient much easier [7].

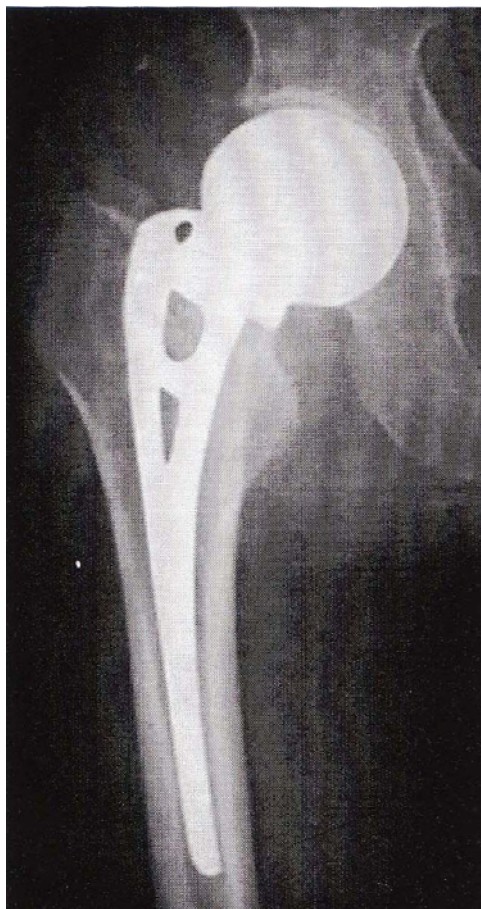

Fig. 3. Hemiarthroplasty

Cases in which arthroplasty in femoral neck fractures is recommended:

- when the fracture focal point cannot be reduced or is impossible to fix;
 - when internal fixing attempts have failed;

- displaced fractures of the femoral neck older than 48 – 72 hours;

- fractures suffered by patients with neurological problems, with convulsions that cannot be controlled by medical treatment (Parkinson, epilepsy, shock therapy), or by non-cooperative patients or mentally impaired patients;

- neck fracture associated with hip luxation;

- patients with pre-existent hip problems (advanced necroses, rheumatic arthritis or coxarthrosis; for such patients total arthroplasty is recommended;

- patients over the age of 70;

- osteoporosis which could endanger the stability of osteosynthesis;

- other problems which do not allow a second intervention.

We have to mention the fact that the hip ‘endoprotheses’ cost quite a lot. ‘Implanting’ them is, as a rule, a rather delicate operation and requires that the patients should be well prepared for it [1].

The study was carried out in 2013, on a group of 124 patients who had been operated on in the Department of Orthopaedics of the Clinical Emergency Hospital of Braşov County.

The parameters we focused on were the following: the sex and age of the patients, the type of fracture, the surface of the femur where the fracture occurred, and the type of surgery performed.

4. Results and Discussions

The choice of treatment for femoral neck fractures depends upon three factors:

1. The age and fitness of the patient.
2. The type of fracture.
3. The degree of displacement.

With respect to the *sex* of the patients, we noticed that 62% are women and 38% men. As far as *age* is concerned, most are between 60 and 80 years of age, with the following distribution:

- 22.5% patients between 50 and 60 years of age;
- 32.5% patients between 60 and 70 years of age;
- 30% patients between 70 and 80 years of age;
- 15% patients between 80 and 90 years of age.

As concerns the *type of neck fractures* we focused on, 58 (72.5%) were basicervical, whereas the rest of 22 (27.5%) were mediocervical.

By comparing the type of surgery undergone by men and women, we notice that in the case of women hemiarthroplasty with Austin-Moore prosthesis was preferred (76%), whereas in the case of men the percentage of osteosynthesis with screws came close to that of arthroplasty with Austin-Moore prosthesis (46%).

The distribution of patients according to the type of surgery they underwent is as follows:

- 62.5% hemiarthroplasty with Austin-Moore prosthesis;
- 20% osteosynthesis with screws;
- 7.5% arthroplasty with total cemented prosthesis;
- 5% osteosynthesis with Ender rod;
- 2.5 % osteosynthesis with Gamma rod;
- 2.5% osteosynthesis with endomedular rod.

Out of the total number of femoral neck fractures we investigated, 62.5% affected the left hip, whereas 37.5 affected the right one. In both basicervical and mediocervical fractures, hemiarthroplasty with Austin-Moore prostheses is preferred.

Femoral neck fractures occur basically among people over 50, but they become more frequent in the case of persons over 60 years of age.

Most of the femoral neck fractures affect women due to the association of the senile

osteoporosis with the endocrinological one. For the same reason the percentage of women with hemiarthroplasty is much higher than that of women with osteosynthesis.

In 1979 Søreide compare the results of screw fixation with those of hemiarthroplasty. His conclusion was that hemiarthroplasty is preferred in elderly with displaced fractures of the femoral neck [11].

Sikorschi, in 1981, still pleading for hemiarthroplasty [10].

Hunter in 1983, believes that it is more appropriate to fix primitive all fractures and arthroplasty is reserved for possible complications of internal fixation. It will avoid a major surgical procedure in the elderly [8].

Welch is the advocate of hemiarthroplasty, that is acceptable in terms of hip function, complications and reinterventions. Thus avoids from the beginning the osteonecrosis and pseudarthrosis [12].

Bray, in 1988, comparing internal fixation (with Knowles brooches) with bipolar hemiarthroplasty, the results of hemiarthroplasty seems superior of percutaneously brooches. His series included a total of 134 patients [4]. We note, however, some controversy.

If Lausten confirms the existence of motion in both joints of the bipolar prosthesis and the reduce of hip wear compared to unipolar hemiarthroplasty, other authors are not as pleased with the results as bipolar prostheses [9].

They show that both joints can be locked. It is gradually diminishing the mobility of external joint or disappearance of intraprosthesis movements. A fibrous tissue interposed between the bipolar cup and the neck edge. In this case the

movements are executed only in external joint and prosthesis behaves as a unipolar one. Conversely, if the blockage is at the movements of external joint prosthesis behaves as total one. Cofiloiditis is considered absent or rare but after some authors 17 can reach 25%. No such revision of bipolar prosthesis is not as easy as thought. In this situation the question arises whether there is an advantage of bipolar hemiarthroplasty compared with unipolar hemiarthroplasty, especially at the elderly, where Davison¹⁸ net tilts in favor of cemented Thompson prosthesis [5].

5. Conclusions

1. Femoral neck fractures are more frequent after the age of 60 (77.5%).
2. The left hip has been affected in 62.5% of cases whereas the right one has been affected in 37.5% of the cases.
3. Women (62.5%) are more affected by such fractures than men (37.5%);
4. The most frequently employed surgical methods were:
 - hemiarthroplasty with Austin-Moore prostheses (62.5%);
 - osteosynthesis with screws (20%).

6. Acknowledgements

Thanks to the Department of Orthopaedics of the Clinical Emergency Hospital of Brasov County for all the support in realisation of this study.

References

1. Alexa, O.: *Tehnici chirurgicale uzuale în traumatismele osteoarticulare (Common surgical techniques in osteoarticular traumathology)*. Iași. Editura Gr.T. Popa U.M.F., 2007.
2. Antonescu, D.: *Elemente de Ortopedie si Traumatologie (Elements of Orthopaedics and Traumatology)*. București. Universitatea de Medicină și Farmacie “Dr. Carol Davila”, 1999.
3. Antonescu, D.: *Patologia Aparatului Locomotor*, vol. 2 (*Musculoskeletal pathology*). București. Editura Medicala, 2008.
4. Bray, T.J.: *Femoral neck fracture fixation: Clinical decision making*. Clinical Orthopaedics (1997), vol. 339, p. 342.
5. Davidson, S.N.J., Calder, J.S., Anderson, H.G., Ward, G., Jagger C., Harper M.W., Greg J.P.: *Treatment for displaced intracapsular fracture of the proximal femur. A prospective, randomised trial in patients aged 65 to 79 years*. In: J. Bone Joint Surgery (2001), vol. 83B, p. 206.
6. Guyton, L.J., Crackarell J.R.: *Fractures of Acetabulum and Pelvis*. In: *Campbell Operative Orthopaedics*, Mosby-Year Book, 10th edition 2003, p. 457-465.
7. Hardinge, K.: *The direct lateral approach to the hip*. In: J. Bone Joint Surg. (1982), Vol. 64B, p. 17.
8. Hunter, G.A.: *Rationale for internal fixation and again hemiarthroplasty. The hip-proceedings of the eleventh open meeting of Hip Society*. Mosby, Saint Louis. Ed. Hungerford, 1983.
9. Lausten, G.S., Vedel, P., Nielsen, P.M.: *Fractures of the femoral neck treated with bipolar endoprosthesis*. In: Clinical Orthopaedics (1987), vol. 218, p. 63-67.
10. Sikorski, J.M.: *Internal fixation vs hemiarthroplasty far displaced subcapital fracture of femur. A prospective randomized study*. In: J. Bone Joint Surgery, (1981), vol. 63B, p. 357.

11. Soreide, O., Mølster, A, Raugstad, T.S.: *Internal fixation vs primary prosthetic replacement in acute femoral neck fractures. A prospective randomized clinical study.* In: Br. J. Surg. (1979), vol. 66, p.56-60.
12. Welch, R.B.: *The rationale for hemiarthroplasty in the treatment of fractures of the femoral neck in elderly patients. The hip-proceedings of the 12th open meeting of the Hip Society.* Ed. Hugerford, Mosby, Saint Louis, (1983), p. 276-278.