

RETROPERITONEAL ABSCESS FOLLOWING APPENDECTOMY: A CASE REPORT

L. VIDA¹ A. MIRONESCU¹

Abstract: *Retroperitoneal abscess is an uncommonly encountered clinical condition, either in adults or, especially, in children, with a non-specific clinical presentation and marked by considerable morbidity and mortality. We report the case of a 15 year old patient who presented with a retroperitoneal abscess involving the psoas muscle, following an appendectomy performed 4 years ago. The patient's case serves as a reminder that retroperitoneal abscess is a uncommon condition that presents with vague clinical features, often resulting in diagnostic delays; the key clinical work-ups are the ultrasound or computed tomography exam of the retroperitoneal space. Of particular interest is the unusually long interval between the initial appendectomy and the onset of the retroperitoneal abscess clinical manifestations.*

Key words: *Retroperitoneal abscess, Appendectomy, Diagnostic delay.*

1. Introduction

Retroperitoneal abscess is an uncommon condition in the pediatric population; the most encountered situation is one of a *primary abscess*, probably as a result of the hematogenous spread of an infectious process from an occult source in the body, the most common causative organism in these cases being *Staphylococcus aureus*. *Secondary abscesses* are less frequent and are caused by the extension of the infection of a nearby structure, namely the gastrointestinal or the genitourinary tract; Crohn's disease is the commonest cause for this type of abscess, and the fecal flora is often incriminated. Patients who had procedures performed in the inguinal or the lumbar areas are also at risk of developing

a retroperitoneal / ilio-psoas abscess.

The diagnostic is difficult to make, due to the rarity of this clinical entity in children, its typical insidious onset, as well as variable and non-specific clinical presentation. Thus, the main diagnostic tools reside in imagistic studies, namely the Ultrasound (US) and the Computed tomography (CT) scan.

The treatment consists in appropriate antibiotherapy in conjunction with adequate drainage of the abscess - either percutaneously (CT or US guided), or operatively.

We report the case of a 15 year old girl who presented with a retroperitoneal abscess involving the right psoas muscle, following an appendectomy performed 4 years ago.

¹ Braşov Children Hospital, Faculty of Medicine, *Transilvania* University of Braşov.

2. Case presentation

A 15 year old girl presented in the emergency room with a right lower abdominal quadrant and right lumbar region pain with fever. The onset of symptoms was insidious, with progressively worsening pain over the last 24 hours; the pain was exacerbated in upright position.

Her past medical history showed an open appendectomy procedure performed in another institution four year ago, followed, one year later, by an open drainage for a residual intraperitoneal abscess, followed by the patient's good recovery. Still, the teenage girl described, occasionally, right flank pain of mild intensity that ceased spontaneously without any medication.

Physical examination at recent presentation showed antalgic position with flexion of the right hip, tenderness in the right flank and iliac fossa during abdominal palpation, but no signs of peritoneal irritation; moderate tenderness in the right loin on pressure. Immediately above the completely healed McBurney's incision scar, a moderately painful mass could be palpated.

Baseline investigations showed a leukocytosis of $13990/\mu\text{L}$ with neutrophilia at $11970/\mu\text{L}$ (85.5%) and an elevated C-reactive protein of 15.91 mg/dL; hemoglobin level of 11 g/dL.

The urinalysis revealed 12-14 white cells per field and 8-10 erythrocytes per field.

The abdominal ultrasound scan revealed a hypo-echogenic intra-abdominal mass of 4 cm in diameter, situated 2 cm deep in the right iliac fossa, containing un-homogenous fluid (Figure 1) and absence of free fluid in the peritoneal cavity. Both kidneys presented enhanced reflectivity and showed no kidney pelvis dilation.

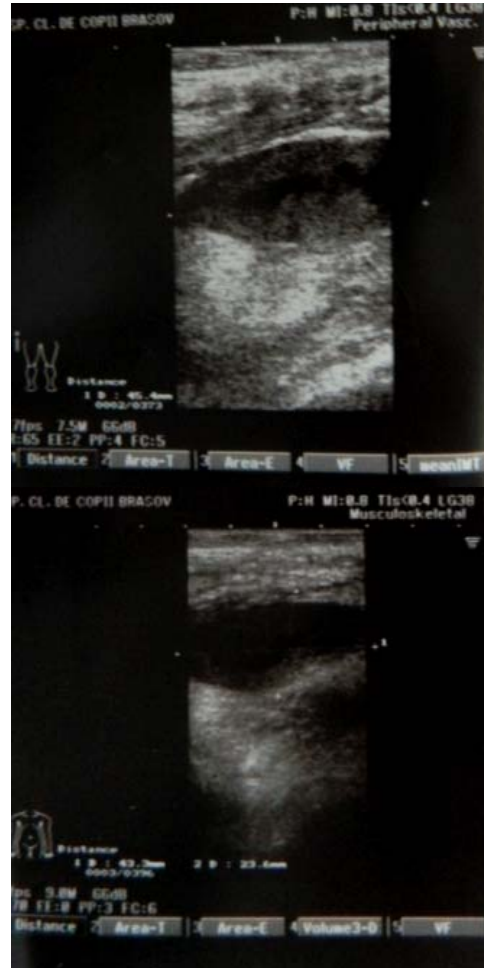

Fig. 1. *Abdominal ultrasonography showing a collection in the right lower quadrant*

Following the above findings, the patient was admitted with the diagnostic of a post-appendectomy residual abscess and started immediately antibiotic therapy with Ceftazidime and Gentamicin.

At the operation, the same approach was used as with the previous procedures (the McBurney incision); except for some adhesions between the greater omentum and the inner surface of the anterior abdominal wall, as well as with the cecum, adhesions that were all freed, there was no

intraperitoneal mass or collection found. At this point, the operation was concluded.

During the next two days after this procedure the patient's condition was not improving; she described further pain in the right lower quadrant and was still febrile, around 39°C. The third day she presented 39.6°C fever, a leukocytosis of 11700 / μ L with 77.3% neutrophilia and an C-reactive protein value at 20.77 mg/dL. The ultrasound reexamination described the same intraabdominal mass as previously, measuring 5/4 cm, located in

the right iliac fossa, near the posterior abdominal wall.

The abdominal CT scan with contrast showed a multiloculated collection in the right lower quadrant, with diameters measuring 17 cm cranio-caudal, 6.5 cm antero-posterior and 7 cm the transverse. This mass was situated retroperitoneal and came in contact, without having clear demarcation, with the psoas muscle that had a thickened aspect; the collection extended cephalad to the inferior pole of the right kidney (Figure 2, 3 and 4).

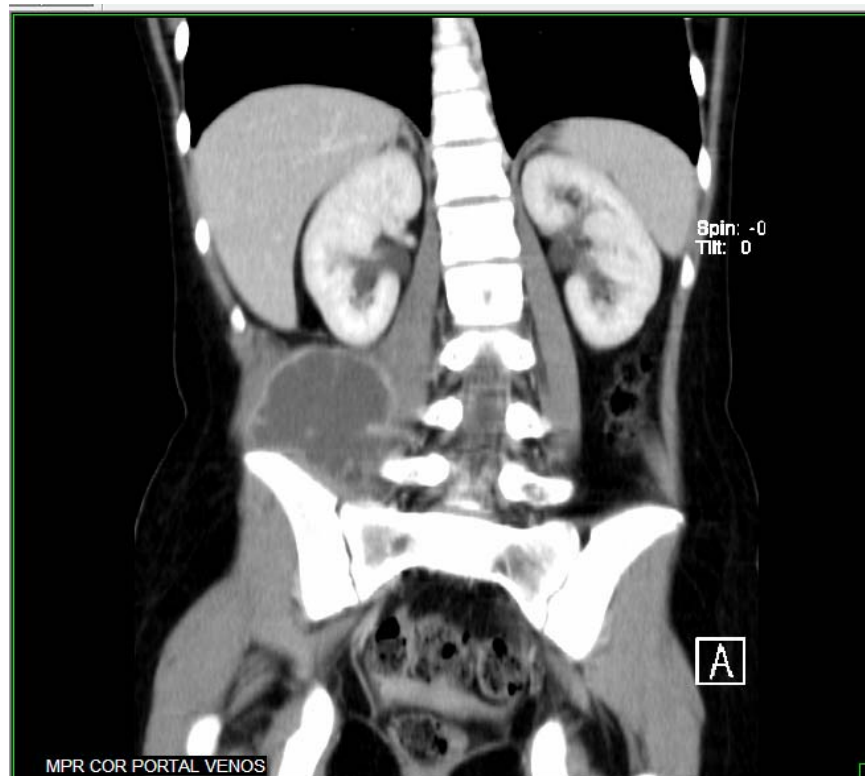


Fig.2. *CT scan with contrast, coronal view, showing a gross loculated retroperitoneal collection in the right lower quadrant. The mass comes in contact with the iliopsoas muscle and extends cephalad to the inferior pole of the kidney.*

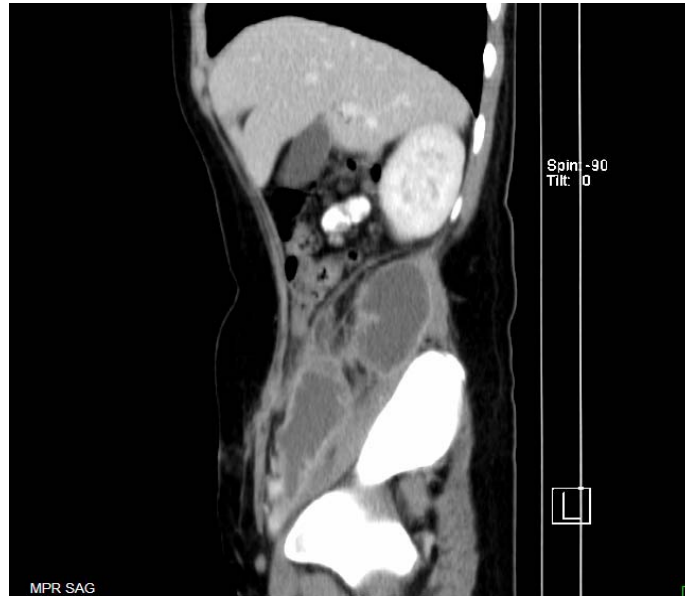

Fig. 3. *CT scan with contrast, sagittal view, showing a gross loculated retroperitoneal collection in the right flank. The mass comes in contact with the iliopsoas muscle while extending cephalad to the inferior pole of the kidney and caudal to the deep inguinal ring.*

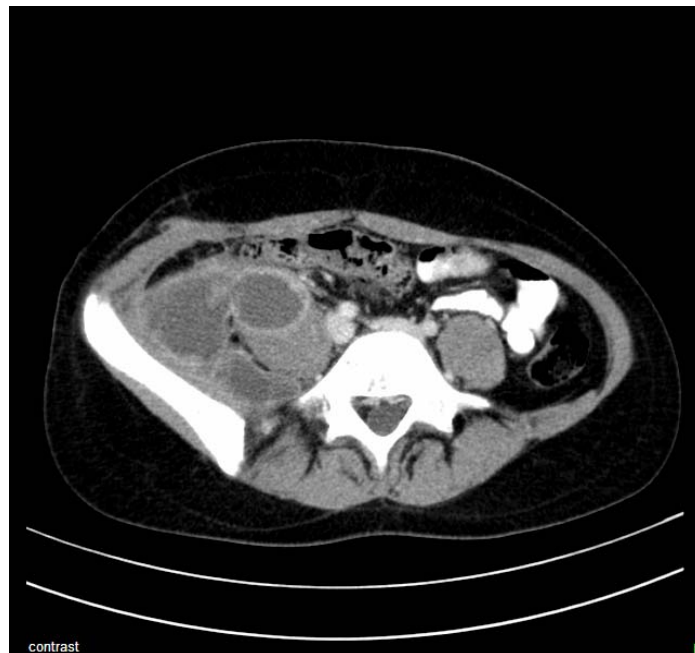

Fig. 4. *CT scan with contrast, transversal view, showing a gross loculated retroperitoneal collection in the right flank, coming in contact with the iliopsoas muscle which is swollen.*

This time the diagnostic of a retroperitoneal abscess was obvious, and another surgical procedure was performed the next day.

Upon entry in the peritoneal cavity, a bulging mass in the right paracolic gutter was noted; following an incision of the posterior peritoneum at this level, the retroperitoneal compartment was entered, with the evacuation of a large amount of grey-yellowish pus, after digitoclasy. The residual cavity extended from the inferior pole of the kidney to the deep inguinal ring; after extensive debridement followed by lavage with warm saline, two drainage tubes were left in place.

The previous antibiotic scheme was replaced with piperacillin - tazobactam and ceftazidime.

During the next couple of days, the patient's condition readily improved, with the diminished abdominal discomfort and cease of high fever; the inflammatory markers decreased to normal. The drain tubes were removed the 6th day postoperatively; the pus specimen taken during the last surgery identified *Escherichia coli* and *Streptococcus faecalis*.

The patient was discharged the 9th day after the surgery and had no further complaints at the 2 weeks, 3 months and respectively 6 months follow-up.

3. Discussions

Retroperitoneal abscesses are uncommon in the pediatric practice; *primary abscesses* are most frequent, ranging between 74–91% of cases [1], [5], [7]. The *secondary abscesses* are less common and are related to nearby pyogenic processes; most commonly they are associated with Crohn's disease, but other causes include renal abscesses, appendicitis, colitis, diverticulitis, or bone infections such as sacroiliitis, septic arthritis and vertebral osteomyelitis.

Unlike the intraperitoneal region that is accessible to auscultation, palpation and percussion, the retroperitoneal compartments are relatively “hidden” to the examiner, making the clinical diagnosis hard to perform – as seen in our case presentation. In addition, the low incidence of this condition, its insidious onset and its variable and non-specific clinical presentation makes it even harder to diagnose.

The classic clinical triad consisting of prolonged fever, back pain, and limp is present in only 30% of the patients with retroperitoneal iliopsoas abscess [2], and was not present in our case. Other clinical features are flank/abdominal pain, malaise, weight loss and the presence of a lump in the groin [2].

Of great value is the positive psoas sign, which is attributed to inflammation causing spasm of the psoas muscle, and femoral neuropathy, which includes a limp or a flexion deformity of the hip. Some patients may present a swelling below the inguinal ligament or a mildly tender mass in the lumbar region or in the flank.

As it happened in our case, the imaging studies have a crucial role in establishing the right diagnosis. Ultrasound is diagnostic in only 60% of the cases [3], [6], owing to the fact that the retroperitoneal space can be difficult to visualize ultrasonically, especially in the presence of gas; it is also extremely operator dependent. Computed tomography should be done for definitive diagnosis and is considered the “gold standard” [8], whereas magnetic resonance imaging is superior, but also more expensive.

The treatment of retroperitoneal abscesses consists of appropriate antibiotic therapy in conjunction with drainage of the collection. The antibiotic scheme depends on the type of abscess, having in mind that *Staphylococcus aureus* is the causative agent in 88% of patients with primary abscesses, whereas *Escherichia coli* and *Streptococcus*

faecalis are held responsible for most secondary retroperitoneal abscesses [6].

The draining method of choice is computed tomography or ultrasound guided percutaneous drainage, while surgical drainage is advisable for multiloculated collections and in the presence of other intra-abdominal pathology which requires concomitant surgery [4].

4. Conclusions

Retroperitoneal abscess is a rare, but serious complication following appendectomy, often mistaken for other conditions. Given its low incidence and non-specific presentation, a high index of suspicion along with imaging studies (especially computed tomography) are needed to avoid diagnostic delays and even unnecessary abdominal exploratory surgery. Although very uncommon, a long time interval – even years - between the initial appendectomy and the onset of clinical manifestations of the retroperitoneal abscess can pass, thus making the diagnosis even more difficult.

Therefore, clinicians should always keep in mind the possibility of this long-term complication following an appendectomy as the cause of recurrent right lower quadrant pain.

Acknowledgements

This paper was presented at the “Al V-lea Congres Naţional al Societăţii Române de Chirurgie Pediatrică” in octomber 2013 in Alba – Iulia.

References

1. Bresee, J.S., Edwards, M.S.: *Psoas abscess in children*. In: *Ped Infect Dis* 1990, 9:201-206.
2. Chern, C.H., Hu, S.C., Kao, W.F., et al.: *Psoas abscess: making an early diagnosis in the ER.*. In: *Am J Emerg Med* 1997, 15:83–8.
3. Huang, J.J., Ruaan, M.K., Lan, R.R., et al.: *Acute pyogenic iliopsoas abscess in Taiwan: clinical features, diagnosis, treatments and outcome*. In: *J Infect* 2000, 40:248–55.
4. Kang, M., Gupta, S., Gulati, M., et al.: *Ilio-psoas abscess in the paediatric population: treatment by US-guided percutaneous drainage*. In: *Pediatr Radiol* 1998, 28:478-81.
5. Prassopoulos, P.K., Giannakopoulou, C.A., Apostolaki, E.G., Charoulakis, N.Z., Gourtsoyiannis, N.C.: *Primary ilio-psoas abscess extending to the thigh in a neonate US, CT and MR findings*. In: *Pediatr Radiol* 1998, 28:605-607.
6. Ricci, M.A., Rose, F.B., Meyer, K.K.: *Pyogenic psoas abscess: worldwide variations in etiology*. In: *World J Surg* 1986, 10:834–43.
7. Schwaitzberg, S.D., Pokorny, W.J., Thurston, R.S., McGill, C.W., Athey, P.A., Harberg, F.J.: *Psoas abscess in children*. In: *J Pediatr Surg* 1985, 20:339-342.
8. Zissin, R., Gayer, G., Kots E., et al.: *Iliopsoas abscess: a report of 24 patients diagnosed by CT*. In: *Abdom Imaging* 2001, 26:533–9.