

URETERORENOSCOPY: INDICATIONS AND COMPLICATIONS - A RETROSPECTIVE STUDY

L. MAXIM^{1,2} I.A. BĂNUŢĂ² I. SCÂRNECIU^{1,2}

Abstract: Ureterorenoscopy (URS) is a common procedure in the urological practice. The objectives of this retrospective study were to investigate number of patients who underwent ureteroscopy and also to point out the complications of this procedure. 148 ureteroscopy were performed and we identified 86 (58,10%) cases in the year 2015 and 62 patients (41,89%) in the year 2016. The female/male ratio: 63 (42,56%): 85 (57,44%). The mean patient age was $55,4 \pm 8,2$ in the female group compared to $61,2 \pm 8,6$ in the male group. All ureterorenoscopy were done in therapeutic (136 cases, 91,9%) or diagnosis (12 cases, 8,1%) purpose. The incidence of the complications was 12,2 %. Rigid ureteroscopy is a procedure that is demonstrated to be safe and efficient and it can easily be carried out to treat upper urinary tract calculi or other pathologies.

Key words: ureterorenoscopy, ureteral stones, ureteral JJ stent.

1. Introduction

Ureterorenoscopy (URS) is a common procedure in the urological practice. The technique was first described by Hugh Hampton Yang in 1912, using a rigid cystoscope [9]. Improvements in the ureteroscopy design have made this technique a high success rate procedure with minimum morbidity and mortality [5]. Urinary calculi are a common disease, affecting the patients in a ratio of 3 males to 1 women, with a higher incidence between 40 and 50 years of age. Ureteroscopy can be performed in case of ureteral calculi or kidney calculi, being thus a serious alternative to percutaneous

nephrolithotomy [6]. The endoscopic treatment of lithiasis is a technique with low morbidity, between 5 and 10 % [4].

2. Objectives

The objectives of this retrospective study were to investigate number of patients who underwent ureteroscopy and also to point out the complications of this procedure in the Emergency County Hospital, Braşov Clinic of Urology.

3. Material and Method

The retrospective study was performed between 01 January 2015 – 30 October

¹ Clinic of Urology, Emergency County Hospital, Brasov.

² Department of Medical and Surgical Specialties, Faculty of Medicine, University Transilvania Brasov

* Correspondent author: alexandru.banuta@yahoo.com

2016 at Emergency County Clinical Hospital. The hospital medical registry was reviewed for records of patients undergoing ureterorenoscopy. The inclusion criteria were: male and female patients above 18 years old who had undergone ureterorenoscopy. It was included also information regarding patient demographic, characteristics of their disease, details of surgery and postoperative period.

All patients underwent laboratory and radiographic investigations (complete blood count, renal function test, urography, reno-vesical x-ray, ultrasound, computer tomography). The follow-up data was collected and included information regarding: location of double J stent (if it was placed), results of laboratory investigations, presence of residual fragments, presence of postoperative complications, days of hospitalization. Postoperative complications included: urinary infection/sepsis, urine reflux, hematuria.

The ureterorenoscopy performed in our center were made after obtaining the informed consent forms signed by all

patients. The form of anesthesia used in most of patients was general sedation, while in other selected cases we used spinal anesthesia.

Antibiotherapy (third generation cephalosporin) were given to all patients before sedation and it was maintained at least 24-48h after anesthesia.

We used a rigid ureteroscope (Karl Storz) as showed in Figure 1. The small calculi were removed intact with forceps, while the large calculi were fragmented with ballistic lithotripter in order to be eliminated. The disintegrated fragments were either removed artificially (with forceps) or spontaneously eliminated. Depending on the patient condition and the medical decision, at the end of the procedure a double J stent was placed.

3. Results

Between 1 January 2015 and 30 October 2016, 148 ureteroscopy were performed in our clinic. The demographic characteristic of the patients is showed in Table 1.

Demographic characteristics of the study group

Table 1

GENDER	YEAR		MEAN AGE	MEAN BMI
	2015	2016		
FEMALE	36 (41,8%)	50 (58,2%)	55,4± 8,2	28,2 ±3,6
MALE	27 (43,5%)	35 (56,5%)	61,2± 8,6	27,4±4,1

After the analysis of the study data we identified 86 (58,10%) cases in the year 2015 and 62 patients (41,89%) in the year 2016. We consider important the analysis of the male/female ratio: 63 (42,56%)

females and 85 (57,44%) males. The mean patient age was 55,4 ± 8,2 in the female group compared to 61,2 ± 8,6 in the male group.

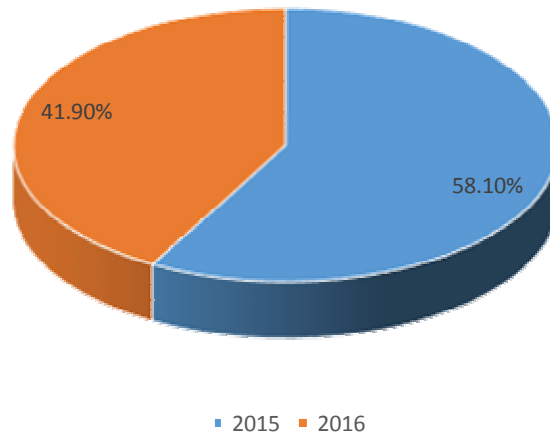


Fig. 2. Distribution of patients according to the year of study

All ureterorenoscopy were done in therapeutic (136 cases, 91,9%) or diagnosis (12 cases, 8,1%) purpose. In

figure 3 are identified all the indications for ureteroscopy included in this study.

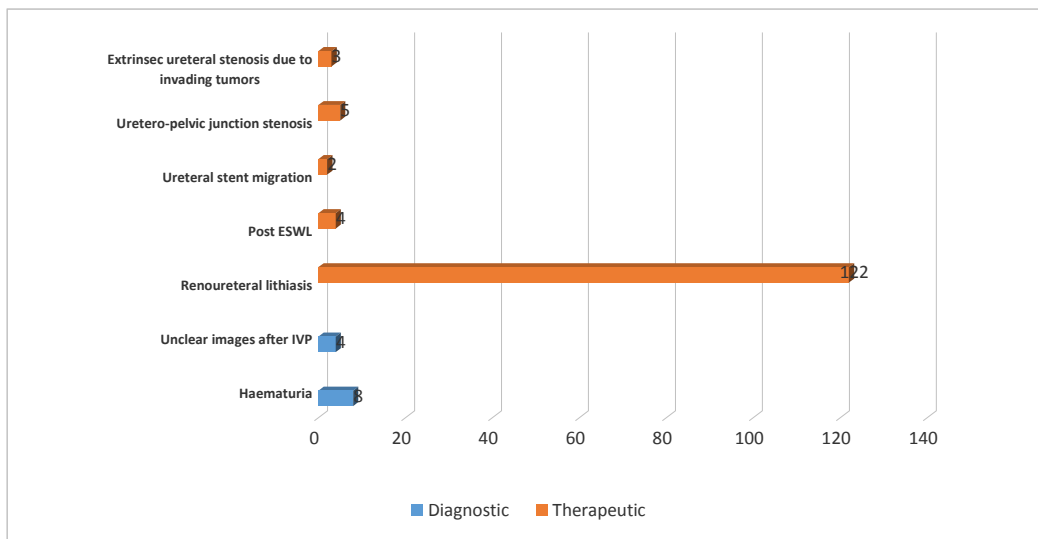


Fig.3. Distribution of ureteroscopies regarding their purpose

In our clinic, we performed diagnostic ureterorenoscopy in order to determinate the etiology of undiagnosed by other methods, of hematuria in 8 cases (5,4%) or in case of unclear images after intravenous pyelography (4 cases, 2.7%).

The ureterorenoscopy procedure was used in therapeutically purpose in 136

cases (91,9%) in Emergency County Clinical Hospital. The indications for intervention were: Reno ureteral lithiasis (122 cases), post ESWL (4 cases), ureteral stent migration (2 cases), ureteropelvic junction stenosis (5 cases), and extrinsic ureteral stenosis due to invading tumors (3 cases).

Reno ureteral calculi:

Ureterorenoscopy was the main indication for ureteral stones, the procedure being necessary in 122 cases (89,7%). In 112 cases (91,8) we found single ureteral stones while in 10 cases (8,2%) we identified multiple stones. Using this procedure for the treatment of ureteral lithiasis we had stone-free rate of 81,2%. It is also well known that the migration of the proximal ureteral calculi are a cause of ureteroscopy failure, in our study we identified 4,05% cases. In a percentage of 74,6% cases we identify residual fragments after ureteroscopy and we applied double J stent. The rate of postprocedural early complications were 12,2% and were represented by: persistent hematuria, ureteral reflux, septic complications.

Uretero-pelvic junction stenosis

We performed ureteroscopy in 5 cases (3,6%) of uretero-pelvic junction stricture. Primary stenosis was found in 4 cases and secondary stenosis (patients with personal history of pyeloplasty and pyelolithotomy) in 1 case. The average length of the uretero-pelvic junction stenosis was ~ 1 cm

Extrinsic ureteral stenosis due to invading tumors

In 3 cases (2,2%) where it was not possible to pass the stenosis area with the JJ stent, we performed rigid ureteroscopy, which allowed us the installation of the stent.

Ascended ureteral stents

We also found 2 cases (1,4%) of JJ stent ascension, being considered a complication of ureteroscopy or other interventions that required ureteral stenting. In this cases we performed rigid ureteroscopy and it was performed either the stent extractions, either the reposition of the stent.

Post ESWL Stein Strasse

A condition which occurs in the moment when the fragments of the disintegrated calculus in the kidney or upper ureter descends down the ureter and lies one on top of the other appearing like a street packed with stones. We identified this condition in 4 cases (2,9%) We also investigated the cases where, during the ureteroscopy, it was placed a JJ stent.

From the total cases, in 121 it was required a placement of a JJ stent and in 27 cases we didn't performed this procedure. The distribution of the cases is exemplified in Figure 4.

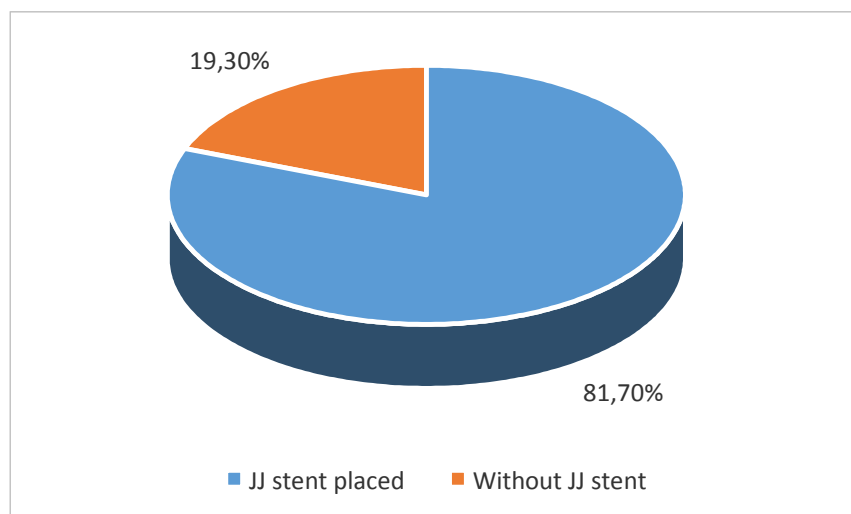


Fig. 4. *Distribution of cases according to the placement of a JJ stent*

The incidence of the complications was another objective of our retrospective study. Our results were according to the literature, with an incidence of 12,2% of complications after ureteroscopy. We

didn't identify any ureteric injury, stricture or ureteric perforation during our study. The distribution of the complications is shown in figure 5.

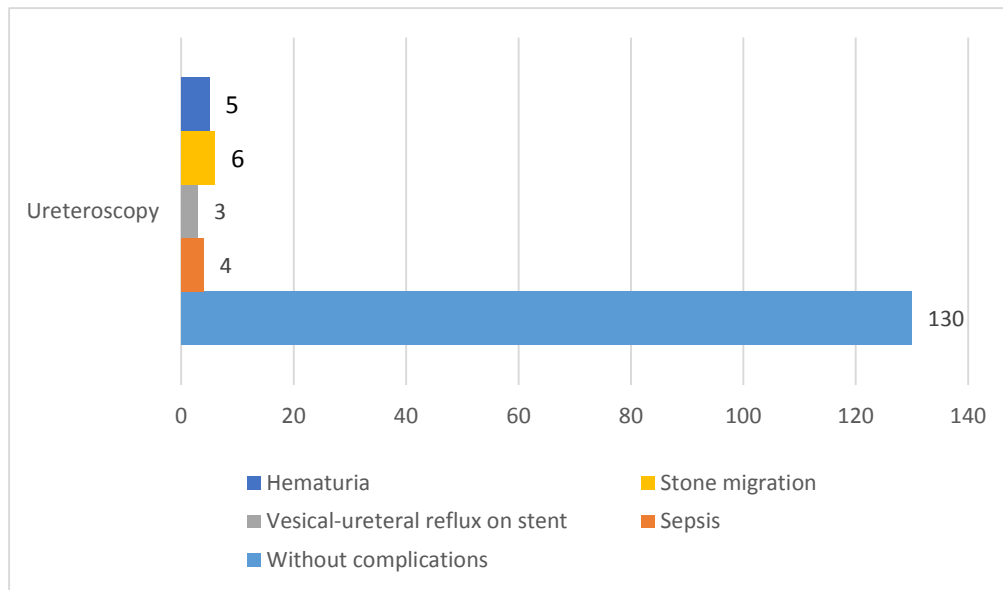


Fig. 5. Distribution of complications of ureteroscopy during the study period

4. Discussions

Since the first use of ureteroscopy in 1912, performed by Hampton Young [9], this technique has developed, becoming a useful method in the management of ureteric calculi, used worldwide but also for other urinary tract pathologies [3]. The technique has become as effective as open surgery, with low rates of mortality and morbidity.

A study of Fasihuddin Q et al from 2002, on 125 patients treated with ureteroscopy pointed out that the fragmentation and extraction of ureteral calculi was successful in 93,8% of cases [2], in 2,5 % it was pointed out a stripping of mucosa [2]. Another study from 2003, on 30 patients with ureteral calculi concluded that the fragmentation of the calculi was done in 95% of cases using ureterorenoscopy [8]. Park et al also

investigated the free rate calculi after ureteroscopy, and concluded that in 87.8% of patients treated with this method, the cases were solved [7]. The technological advances of the ureteroscopy had led to an easy access to the upper urinary tract (kidney and urethra), with the absence of surgical incision. The main advantage of URS is that the contra-indications for this procedure are minimum, almost all areas of the urinary tract being accessible.. The ureteral stricture is the main contraindication for the ureterorenoscopy. The literature points out the benefits of URS, indicating that this procedure has low rates of complications, short hospitalization period and low rates of morbidity and mortality [4].

In the literature, it was also investigated the rate of complications of this procedure. Probably the most feared and also rare complication of ureteroscopy is ureteral

avulsion (< 1%). Common complication reported include post-operative fever, mucosal or ureteric injury, urosepsis, ureteral stricture, hematuria, and persistent vesicoureteral reflux [1], [4].

5. Conclusions

Rigid ureteroscopy is a procedure that is demonstrated to be safe and efficient and it can easily be carried out to treat upper urinary tract calculi or other pathologies. It can reduce the need for admissions and thus cut healthcare costs. The procedure has a low rate of complications. If ESWL is not available, ureteroscopy is a good treatment in an outpatient setting, depending of the stone size and location.

The developments of flexible ureteroscopes diversified the indications and improved the performances of retrograde approach for upper urinary tract pathology.

References

1. de la Rosette, J., Denstedt, J., Geavlete, P., Keeley, F., Matsuda, T., Pearle, M., Preminger, G., Traxer, O.: *The clinical research office of the endourological society ureteroscopy global study: indications, complications, and outcomes in 11,885 patients*. In: J Endourol. 2014; 28:131–139.
2. Fasihuddin, Q., Hasan, A.T.: *Ureteroscopy (URS): an effective interventional and diagnostic modality*. In: J Pak Med Assoc. 2002; 52:510-2.
3. Geavlete, P., Georgescu, D., Mirciulescu, V., Niță, G.: *Ureteroscopic laser approach in recurrent ureteropelvic junction stenosis*. In: Eur Urol., 2007; 51:1542–1548.
4. Geavlete, P., Georgescu, D., Niță, G., Mirciulescu, V., Cauni, V.: *Complications of 2735 retrograde semirigid ureteroscopy procedures: a single-center experience*. In: J Endourol. 2006; 20:179–85.
5. Harmon, W.J., Sershon, P.D., Blute, M.L., Patterson, D.E., Segura, J.W.: *Ureteroscopy: current practice and long term complications*. In: J Urol 1997, 157:28–32.
6. Hyams, E.S., Shah, O.: *Percutaneous nephrostolithotomy versus flexible ureteroscopy/holmium laser lithotripsy: cost and outcome analysis*. In: J Urol. 2009; 182:1012–7.
7. Park, H., Park, M., Park, T.: *Two years experience with ureteral stones: extracorporeal shock wave lithotripsy v ureterorenoscopic manipulation*. In: J Endourol. 1998; 13: 501-4.
8. Sanaullah, Kamran T, Zaheer K, Akhtar M. *Pneumatic lithotripsy for the management of ureteric calculi*. In: J Coll Physico Surg Pak. 2003; 13: 101-3
9. Tefekli, A., Cezayirli, F.: *The history of urinary stones: in parallel with civilization*. In: Scientific World J.2013;2013:423964