

ILEOCECAL TUBERCULOSIS - CASE REPORT

C. COBELSCHI^{1,2} M. HOGEA^{1,2} D. PANAIT¹
A. PASCU² C. GAVRIŞ^{1,2} A. MAIER¹

Abstract: *Caecal-appendicular tuberculosis represents a rare localization of tuberculous lesions. Within digestive tract tuberculosis, the ileo-caecal localization is the most frequent, and in many cases is correlated with pulmonary tuberculosis lesions. The increase incidence of tuberculosis worldwide determined a raise in the intestinal tuberculosis rate. Positive diagnosis is based on histopathological and bacteriological examination. The differential diagnosis with inflammatory bowel diseases and intestinal neoplasia is difficult, but necessary for a correct management. Because of an increase in tuberculosis prevalence worldwide, clinicians must acknowledge the existence of intestinal tuberculosis, especially in the case of a non-specific clinical, biological or radiological presentation. Combined efforts of diverse specialists (radiologists, gastroenterologists, surgeons) are recommended in order to early diagnose and treat this disease.*

Key words: *caecal-appendicular tuberculosis, caecal tumour.*

1. Introduction

Tuberculosis is a chronic, transmissible disease, affecting mainly the lungs, but being able to affect any organ. Most frequently, tuberculosis is produced by *Mycobacterium tuberculosis hominis* (Koch's bacillus) and incidentally by *Mycobacterium tuberculosis bovis* [13]. After 1980, the incidence of pulmonary tuberculosis has increased worldwide and led to a consecutive rise in the incidence of abdominal tuberculosis [1], [11].

About 25% of the patients having pulmonary tuberculosis develop extra pulmonary lesions, among which abdominal tuberculosis registers 11% [5], [14]. Intraabdominal tuberculous lesions are most frequently located within lymph nodes, in the genitourinary tract, peritoneal

cavity or in the gastrointestinal tract [8].

Tuberculosis can involve any organ of the digestive tract, but most frequently it affects the ileocecal region [2], [4], [5], [11], [14].

Both clinical and imaging diagnostic is difficult in gastrointestinal tuberculosis. Positive diagnostic is made by microscopic examination, bacterial and histopathological analysis [2], [4], [5], [13], [14]. Differential diagnosis is also necessary and hard to obtain due to similarities between other diseases such as inflammatory bowel disease, intestinal carcinoma and intestinal lymphoma [2], [4], [16].

The treatment of choice for gastrointestinal tuberculosis is represented by tuberculostatic drugs. Surgical treatment imposes in case of complications (obstruction, perforation) or in uncertain diagnosis [4], [11].

¹ Clinical Emergency County Hospital of Braşov.

² Faculty of Medicine, Transilvania University of Braşov.

* Correspondent author: alina.pascu@unitbv.ro

2. Case report

A 63-year-old patient presented to the Emergency Department of Clinical Emergency County Hospital Brasov, with abdominal pain in the right lower quadrant, gurgling stomach, malaise. Medical history showed smoking, Biermer's anaemia and colonic polyp located in the splenic flexure. The patient denied having tuberculosis or tuberculosis contact. Examination revealed a normal-weight patient, with abdominal pain increased by palpation in the right iliac fossa.

Laboratory tests showed: leukocytosis ($8,320/\text{mm}^3$), thrombocytosis ($462,000/\text{mm}^3$), neutrophilia (74.7%, lymphopenia (16.2%); serum sodium = 134 mmol/L; serum potassium = 6.38 mmol/L; serum chloride = 92.8 mmol/L.

Abdominal ultrasound was normal. The CT scan showed opacities in the superior lobe of the right lung, hepatomegaly, a 5 mm cyst in the IVth hepatic segment (Couinaud's classification); both kidneys having cortical cysts, the largest measuring 14 mm; at the caecal level: a solid iodophilic tumour, with circumferential parietal thickening, with important infiltration of the pericaecal adipose tissue; multiple adenopathies: pericaecal (largest diameter – 9 mm), paraaortic, (largest diameter – 7 mm). There was no free peritoneal fluid.

Based on all data, the following diagnostic was made: cecal tumour determining partial stenosis, probably malignant with multiple intraabdominal adenopathies, and liver cyst.

After proper preoperative preparation (diet, mechanical and oral bowel preparation) the surgery was performed under general anaesthesia, through a midline incision. After exploring the peritoneal cavity, a partially stenotic infiltrative-ulcerative tumour was revealed at the level of the caecum having a diameter of approximate 4 cm, with extensive areas of necrosis. Multiple tumours, suggestive for peritoneal carcinomatosis involve both the parietal peritoneum and the visceral

peritoneum of the transverse colon and of the cecal appendix. Multiple adenopathies developed in the mesocolon and pericecally.

A right hemicolectomy with latero-lateral ileotransverse anastomosis was performed. During surgery no incidents or accidents occurred.

Postoperative antibiotic treatment was started, along with antialgic, antisecretory, prokinetic, and local treatment. The patient was discharged in stable condition in the 7th day post-op.

The microscopic examination of the resected bowel revealed colonic and caecal ulcerated mucosa, covered by caseous, leukocytic and fibrinous exudates. Underlying extended areas of caseous necrosis extend transmurally being circumscribed by epithelioid granulomas with Langhans giant cells surrounded by lymphocyte (Figure 1).

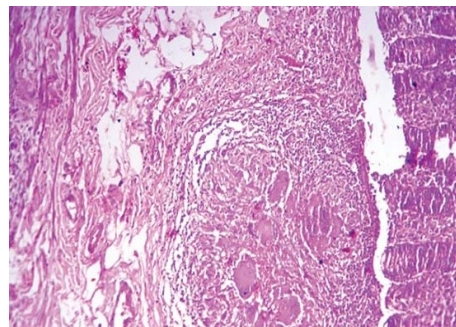


Fig. 1. *Microscopic view of the specimen; hematoxylin-eosin staining*

Caseous granulomatous infiltration of the appendicular wall was also present. The histopathological diagnostic was caeco-appendicular tuberculosis with caseous ulceration. The patient was referred to the specialized health care unit of the Infectious Diseases Department in order to undergo tuberculostatic therapy

3. Discussion

Regarding abdominal tuberculosis, the ileocecal location is the most frequent, its incidence rising with the increase of pulmonary tuberculosis prevalence (8,7

million new cases worldwide in 2011) [1], [4], [11].

Because of abundant lymphatic tissue and faecal stasis the most frequently affected segment of the digestive tract is the ileocecal area [4]. Not all the patients with pulmonary tuberculosis develop digestive disease as well; multiple factors may favour this location: age, race, immune status, related diseases (high risk for those with increased Charlson index). [4], [6].

The symptoms of intestinal tuberculosis are non-specific: abdominal pain (in 65-97% of cases), weight loss (83% of cases), fever (53% of cases), vomiting (60% of cases), diarrhoea (62% of cases), constipation (56% of cases), ascites, fatigue, cachexia, clinical signs of an acute abdomen [5], [12].

Mantoux test can be positive [8]. The radiological appearances specific for active tuberculosis or sequelae may be absent [5], [14]. Ultrasound may reveal ascites [4], [14]. Laboratory tests show a high lymphocyte and leukocyte count and an increased erythrocyte sedimentation rate [5].

Colonoscopy allows visualization of bowel lesions: ulcerative lesions (60% of cases, especially in immunocompromised patients), hypertrophic lesions (10% of cases) [4], [5]. Circumferential ulcero-vegetative and granulomatous lesions are scarcely reported [2], [4].

Based on the clinical data presented is difficult to establish an accurate differential diagnosis between ileocecal tuberculosis and inflammatory bowel disease (Crohn's disease can also determine granulomatous lesions), carcinomas and intestinal lymphomas [2], [4]. More specific for intestinal tuberculosis rather than Crohn's disease is the weight loss and the granulomatous lesions. In Crohn's disease the abdominal pain, intestinal ulceration, strictures and fistulae are more common [4]. The connection between intestinal cancer and intestinal tuberculosis deserves special attention. The pathogenicity of *Mycobacterium tuberculosis* is given by its

invasiveness and ability of intracellular multiplication being resistant to lysosomal enzymes due to somatic antigens [3]. The persistence of bacteria within cells is able to induce DNA damage, thus favouring carcinogenesis [4].

Laparoscopic peritoneal biopsy followed by histological examination is the diagnostic test of choice for entero-peritoneal intestinal tuberculosis characterized by typical peritoneal granulomas (resembling carcinomatous lesions) [5], [11], [14].

Research on identification of rapid diagnostic tests for digestive tract tuberculosis led to new diagnostic methods which have not yet come into current clinical practice: determination of faecal calprotectin, polymerase chain reaction using IS6110 primer sequence, interferon-gamma release assay, and determination of AQP-10 presence in the ileum of patients suffering from intestinal tuberculosis [9], [10], [15].

The treatment of choice for ileocecal tuberculosis is represented by tuberculostatic drugs such as: Isoniazid, Rifampin, Pyrazinamide and Ethambutol [4], [5], [12], [14]. Surgical treatment is reserved for complications (perforation, fistulae, obstruction) and for uncertain diagnosis when the suspicion of malignancy persists [4], [5], [11].

Some of the surgical procedures applied in intestinal tuberculosis are: enterectomy with anastomosis, right hemicolectomy with ileocolic anastomosis, strictureplasty, dissection of peritoneal adhesions. When there is a high risk of anastomotic fistulae two-step surgery is required: enterectomy or right hemicolectomy with ileostomy followed by restoration of the digestive tract continuity during the second surgical step [11].

In this case report the patient had a nonspecific clinical and biological presentation. The absence of tuberculosis in his medical history, no tuberculosis contacts along with the caecal tumour with multiple intraabdominal adenopathies delayed our diagnosis of tuberculosis.

4. Conclusions

Because of a worldwide increase in tuberculosis prevalence, clinicians must acknowledge the existence of intestinal tuberculosis, especially in case of a non-specific clinical, biological or radiological presentation [4]. Additional endorsement and cooperation between gastro-enterologists, radiologists, pathologists and surgeons can lead to an early diagnosis and proper treatment [8], [12], [16].

Surgery has an important role in the diagnostic and therapeutic management of intestinal tuberculosis by means of diagnostic laparoscopy and treatment of complications such as occlusion and perforation.

References

1. Bîrluţiu, V.: *Infecţia HIV şi tuberculoza extrapulmonară (ganglionară mezenterică şi renală – prezentare de caz)* In: Terapeutică, Farmacologie şi Toxicologie Clinică, Anul XII, Vol. 12, Nr. 3/2008, p. 452-455.
2. Cherif, E., Hassine, B.L., Azzabi, S., Khalfallah, N.: *Isolated caecal tuberculosis mimicking a neoplastic tumor in an immunocompetent woman*, In: BMJ Case Rep. 2013 Nov 8.
3. Debeleac, L., Popescu-Drânda, M.C.: *Microbiologie (Microbiology)*. Bucureşti. Ed. Medicală Amaltea, 1994, p. 171-176.
4. Demetriou, G.A., Manojkumar, S.N., Navaratnam, R.: *Concurrent caecal and transverse colonic tuberculosis masquerading synchronous colonic carcinoma*. In: BMJ Case Rep. 2013 May 8.
5. Grigorean, V.T., Iacobini, M.A., Popescu, M., Neacşu, C.M., et al.: *TBC intestinală cu peritonită tuberculoasă – prezentare de caz clinic (Intestinal tuberculosis with tuberculous peritonitis - presentation of clinical case)*. In: AMT, 2009, vol. II, nr. 3, p. 75-77.
6. Hong, K.S., Kang, S.J., Choi, J.K., Kim, J.H., Seo, H., et al.: *Gastrointestinal tuberculosis is not associated with proton pump inhibitors: a retrospective cohort study*. In: World J Gastroenterol. 2013, Jan 14, p.258-64.
7. Larsson, G., Shenoy, T., Ramasubramanian, R., Balakumaran, L.K., et al.: *Routine diagnosis of intestinal tuberculosis and Crohn's disease in Southern India*. In: World J Gastroenterol. 2014 May 7, p. 5017-24.
8. Lee, W.K., Van Tonder, F., Tartaglia, C.J., Daga, C, et al.: *CT appearances of abdominal tuberculosis*. In: Clin Radiol. 2012 Jun p.596-604.
9. Lei, Y., Yi F.M., Zhao, J., Luckheeram, R.V., Huang, S., Chen, M. et al.: *Utility of in vitro interferon – gamma release assay in differential diagnosis between intestinal tuberculosis and Crohn's disease*. In: J Dig Dis. 2013 Feb, p. 68-75.
10. Makesh Kumar, V., Madhavan R., Narayanan, S.: *Polymerase chain reaction targeting insertion sequence for the diagnosis of extrapulmonary tuberculosis*. In: Indian J Med Res. 2014 Jan., p.161-6.
11. Marshall, J.B.: *Tuberculosis of the gastrointestinal tract and peritoneum*. In: The American Journal of Gastroenterology, 1993, p.989-999.
12. Papis, D., Branchi, V., Gomez, L., Herrerias, F., et al.: *Abdominal tuberculosis mimicking Crohn's disease's exacerbation: A clinical, diagnostic and surgical dilemma. A case report*. In: Int J Surg Case Rep. 2015, p.122-5.
13. Rubin, E., Farber, J.L.: *Pathology*, third edition. Philadelphia; New-York. Lippincott-Raven, 1999.
14. Şimon I., Şimon M.: *Tuberculoza abdominală – o dilemă clinică (Abdominal tuberculosis - a clinical dilemma)*. In: Clujul Medical, 2011, Vol 84, Nr.1, p. 83-85.
15. Yamane, T., Umeda A., Shimao H.: *Analysis of recent cases of intestinal tuberculosis in Japan*. In: Intern Med. 2014, p. 957-62.
16. Zhu, Q.Q., Zhu, W.R., Wu, J.T., Chen, W.X., et al: *Comparative study of intestinal tuberculosis and primary small intestinal lymphoma*. In: World J Gastroenterol. 2014 Apr 21, p.4446-52.