

MANAGEMENT OF PERINEAL WOUND POST RECTAL AMPUTATION

I. TOADER¹ C. COBELSCHI^{1,2} A. MIRONESCU²
M. HOGEA^{1,2} A. GHEORGHIU^{1,2} A. MAIER¹

Abstract: *Abdominoperineal resection (APR) involves excision of the distal sigmoid colon and rectum along with mesorectum, peri-rectal fat and lymph tissue and the anal sphincter complex. The most frequent indication leading to amputation of the rectum is adenocarcinoma of the inferior and middle rectum. After APR results the perineal wound presents evolution peculiarities. In efforts of finding an optimal perineal plague approach, more management methods were proposed. In this article the authors present their experience on mesh rectal lodge along with a review of other reported data in the literature.*

Key words: *rectal amputation, rectal lodge mesh*

1. Introduction

Amputation of the rectum or abdominoperineal resection (APR) completely removes the distal sigmoid colon, rectum and mesorectum, all the anal sphincter complex, ischium-rectal fat, and afferent lymphatic tissue, using a two-staged operation: abdominal and perineal. The intervention always ends with definitive left colostomy [2], [6], [7], [8], [10], [12], [14].

Rectum amputation was historically carried out by Konig (1882), Czerny, Braiţev, and improved by Ed. Quenu (1896), Giordano, Charles Mayo (1903) and then Miles (1907), which encoded the "one-piece" amputation technique of organs and tissue [6].

Rectal amputation with definitive left colostomy and inguinal lymphoid

dissection, associated with radiotherapy, is the treatment of choice for low rectum adenocarcinomas, easy accessible on digital rectum examination (on a distance of maximum 8 cm from the anus), neoplasms of the anal canal, squamous cell and basal cell carcinoma. The indication of rectal amputation is addressed to low situated tumours invading the anal sphincter apparatus or to stage T3, T4 which because of their low location do not allow a low anterior resection of the rectum [1], [6], [8], [11].

Rectum amputation is considered the gold standard of treatment for the lower rectum tumours, but the consequence is impaired life quality [5], [15].

Although amputation of the rectum was first described more than 100 years ago, this procedure remains valid in the treatment of rectal cancer, despite modern

¹ Emergency Clinical County Hospital Brasov.

² Faculty of Medicine, *Transilvania* University of Braşov.

* Correspondent author: mircea87@gmail.com

techniques of preservation of the anal sphincter, because it avoids poor anastomoses under certain local and general conditions [5], [7].

Over the years several methods have been described for the treatment of rectal lodge after rectum amputation. Further, we will review some of the alternatives described in the literature and considered more important, and then focus on a very simple process, but with good results: the mesh of the rectal lodge.

According to classical technique, perineal wounds can be closed by suturing the anatomic layers when dealing with an aseptic one, when the tumour is not infiltrative or ulcerative and there is an efficient haemostasis. In this case, the perineal cavity must be drained. However, when dealing with a septic wound, unsatisfactory haemostasis or an infiltrative ulcerative tumour, a Mikulitz bag with meshes should be inserted into the rectal lodge. The meshes should be extracted progressively and the wound should be partially closed [1], [6], [7], [12].

A simpler method that prevents both post-operative bleeding and wound suppuration was described by Prof. Radulescu as follows: "a large field of gauze (in four layers) will be stuffed methodically – compressive, but not excessively - so as to reach the level where the pelvic peritonization can be performed". Subcutaneous fat and skin will be sutured, leaving the minimum space for extracting the field posteriorly [11].

2. Aim of the Study

The purpose of this study is to show the effectiveness of the treatment method of the perineal wound, after amputation of the rectum, using a sterile mesh (soft textile mesh).

3. Material and Methods

We conducted a prospective study on a group of 14 patients who suffered a surgical intervention for rectal cancer in the Surgical section of the County Clinical Emergency Hospital of Brasov, between January 2015 - December 2016. During this study, the short-term postoperative evolution was analysed until the complete healing of the perineal wound.

Pathology related data, surgical technique and immediate postoperative evolution were obtained by analysing patient observation charts, protocols and histopathological results. The follow up data was obtained from the outpatient clinic.

4. Results

We performed 14 rectum amputations on patients diagnosed with rectal tumours located in the lower and middle part of the rectum, between January 2015 and December 2016.

Of the 14 patients, 9 were male (64.28%).

From an age perspective, 2 patients were aged between 50 and 59, 4 patients were aged between 60 and 69, 6 patients were aged between 70 and 79, and 2 patients were aged between 80 and 89.

The most common reasons for referral to medical appointments were: rectal bleeding (12 of the 14 patients, 85.71%), changes in bowel transit (9 of the 14 patients, 64.28%) and rectal tenesmus (8 of the 14 patients, 57.14%).

Due to the low location of the rectal tumours in all 14 cases studied (less than 6 cm from the anal orifice), the diagnosis could be established easily by digital rectal examination. A number of 8 patients had both a colonoscopy and a biopsy for preoperative histopathological diagnosis. CT examination was performed on 9 of the 14 patients during

hospitalization, significantly contributing to tumour staging and tumour removal possibilities. Of the 9 patients who were examined through CT, 2 were diagnosed with lung nodules without a certainly pathological nature, 1 patient with infracentimetric hepatic nodular lesions and another one with retroperitoneal lymphadenopathy.

A total of 8 of the 14 patients had a confirmed histopathologic diagnosis of adenocarcinoma. For the other 6 patients, rectum amputation was recommended on the basis of the macroscopic characteristics of the malignant tumour (tumour stenosis, vegetative ulcerative, bleeding tumours or imminent bowel obstruction).

In all 14 cases, the classic technique of amputation of the rectum - abdomino-perineal resection Milles - was applied. This consisted in the bulk removal of the distal sigmoid colon, rectum together with the mesorectum, and of rectal afferent lymphatics associated with ischium-rectal fat) with definitive left colostomy on sigmoid colon. Using about 4-6 sterile rectal meshes and the wound was partially sutured in the perineal part, leaving place for the subsequent extraction of the meshes. (Fig.1)

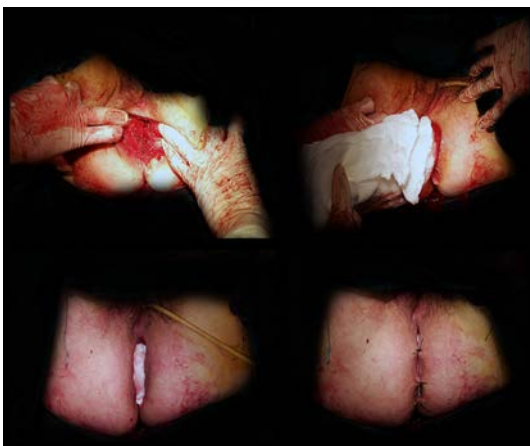


Fig. 1. Mesh placement

No incidents or accidents occurred during surgery and the postoperative evolution was favourable in all 14 cases.

There were no immediate postoperative complications.

The meshes were removed 4-5 days after the surgery under general i.v. anesthesia, after the removal of 1-2 sutures at the inferior pole of the wound. It must be specified that the meshes were not allowed to be replaced in the rectal lodge and the rectal wound was not secondary sutured.

Daily perineal toilet of the perineal wound was performed with saline serum, betadine or chlorhexidine and sterile dressings.

Patients were discharged in full healing process with recommendations to change dressings daily, followed by changing the dressing every 2-3 days in the surgical ambulatory. The remaining sutures were removed approximatively 14 days after surgery, taking into account the healing process of the wound. The hospitalization period was between 11 and 29 days, with an average of 17 days.

The complete healing of the perineal wound was achieved in 6-8 weeks.

In all 14 cases, the histopathological diagnosis after examining the resected sample was adenocarcinoma. All the examined tumours had a differentiation G2 stage. The number of lymph nodes that were excised was between 2 and 20, with an average of 10 nodes. The number of positive neoplastic invaded nodes were between 0 and 6. Depending on the classification pTNM, there were 5 cases in stage I, 3 cases in stage II and 6 cases in stage III.

All patients were referred to the Oncology Department.

5. Discussions

APR is one of the most demanding

procedures found in gastrointestinal surgery. Since it was first described, this technique suffered only slight modifications [9].

Currently, the literature describes many ways of wound treatment after APR, such as:

- closure of the anatomical planes with wound drainage, perineal or transabdominal contra incision.

- reconstruction of the pelvic floor performed with mesh material or non-resorbable material followed by direct closure of perineal wound. After this process, adhesions frequently occur between the small intestine and synthetic material. Attempts were made to use human acellular dermal matrix to reconstruct the pelvic floor, but it was found that, in time, this technique developed tissue laxity which led to incisional hernias.

- use of the omental patch to fill the pelvic cavity which remained after rectum amputation did not provide any significant advantage.

- closing the pelvic cavity with myocutaneous flaps using rectus abdominis muscle (the patient is likely to develop post incisional hernia), gluteal muscle (patient may develop functional sequelae – force reduction in limb extension) or gracilis muscle (limited use due to its variability of blood supply). These techniques have not been applied because they are laborious, require a prolonged intervention time along with a team specialized in reconstructive surgery [13], [16].

The high incidence of wound complication post APR is not surprising. APR resulted in the formation of dead space within the pelvic cavity where blood clots and fluids may accumulate, rising the development of wound infection, pelvic abscesses, and fistulas. Surrounding rigid structures of the pelvic region do not

favour the closure of the perineal wound. The primary closure of the wound is usually under tension and is an important factor for wound dehiscence. However, it does not explain the large number of post APR perineal wound complications (14%-80%). Complication of the perineal wound post APR is common. Risk factors include: surgical technique, pre-operative radiotherapy, indication of surgery (rectal cancer, anal cancer). Other risk factors include diabetes, smoking, obesity and wound management during the intervention. The perineal wound represents an independent risk contributor to the major postoperative complications. Despite improvement of the surgical techniques, perineal wound dehiscence is reported to be higher than 10%. The anatomy of the pelvic floor and the risk of infection post APR is associated with a high rate of wound healing problems after rectum amputation [9], [16].

Christian et al. conducted a study on 153 patients with rectum amputation and major complications of the perineal wound (wound dehiscence > 2cm, perineal abscess or any other complication requiring reintervention procedures) that were associated with an increased body mass index, diabetes and the tumour stage. Minor complications (wound dehiscence < 2cm, wound infection or fistula) were associated with amputation of the rectum and with high body mass index [3].

Perez-Luna S. et al. conducted a study on 137 patients looking at the morbidity and mortality after rectum amputation, concluding the following: abdomino-perineal resection for adenocarcinoma of the lower rectum is a surgical procedure associated with significant morbidity but low postoperative mortality. The main cause of postoperative morbidity was influenced by perineal wound infection, radiotherapy, chemotherapy and age above 55 years. However, the treatment was

associated with a low rate of local recurrence [4].

Pramateftakis et al. conducted a study on 75 patients with rectum amputation; the perineal wound was drained with drainage tubes. In 42 cases (56%) the drainage tube was exteriorized through the wound, and in the other 33 cases (44%) the drainage tube was exteriorized by perineal contra-incision. Passive drainage was used. The wound was closed primary in two layers. Drainage was maintained until the amount of fluid drained dropped below 50 ml for 5-7 days. After 5-7 days the drainage was suppressed regardless of the amount of fluid drained to prevent infections. Specific postoperative complications were observed in 23 patients. The incidence of perineal wound healing disorders was significantly higher in the group in which the drain was exteriorized through the wound. Of this group, 14 patients had a delayed perineal wound healing (11 patients with complete healing process was between 25-40 days, while the other 3 patients developed a permanent fistula). In cases where the drain was exteriorized by perineal contra-incision, complete wound healing occurred in 10 days and no healing disorders were noted, even though in this group some of the patients underwent chemotherapy +/- radiotherapy [9].

In our study there were no perineal wound complications during the follow-up (6-8 weeks). The depth of the perineal wound required a longer healing period until epithelialization, a period considered to be normal. The small number of such cases (14) in the study group does not allow postulating rectal lodge as the best approach. This requires a multi-centric extension of the study.

6. Conclusions

The results of our study and of other similar studies reported allow us to conclude

the following advantages and disadvantages of drainage lodge rectal soft fields.

Advantages:

- It is a simple technique to achieve;
- Very effective control of haemostasis, shortening cycle time and intervention;
- Ensures an efficient drainage of the remaining cavity, reducing the need for the drainage tubes application, both intraperitoneal and intrapelvic;
- No noticed wound complications;
- Reduced hospitalization by avoiding postoperative complications;
- Although apparently long perineal wound care increases hospital costs, this increase is cushioned by the low rate of complications.

Disadvantages:

- Longer perineal wound healing;
- The need of dressings and mesh, initially daily, then every 2-3 days as the wound is closed (we aim for depth to the surface wound closure);
- Increased risk of bowel occlusion, mentioned by other authors. In our study group we did not record this complication.

In conclusion, we recommend lodge rectal dressing as a simple and safe drainage and haemostasis method.

References

1. Angelescu, N., Popa, F.: *Caiete de tehnici chirurgicale*. Vol. 2. București. Editura Medicală, 2010.
2. Angelescu, N.: *Tratat de Patologie Chirurgicală*. București. Editura Medicală, 2003.
3. Caprice K. Christian, Kwaan, Mary R., Betensky, Rebecca A. et. al.: *Risk Factors for Perineal Wound Complications Following Abdominoperineal Resection*. In:

- Diseases of the Colon & Rectum, (2005); 48(1), p. 43-48.
4. Luna-Perez, P., Rodriguez-Ramirez, S., Vega, J., et al.: *Morbidity and mortality following abdominoperineal resection for low rectal adenocarcinoma*” In: *Revista de Investigacion Clinica; Organo del Hospital de Enfermedades de la Nutricion* (2001); 53(5), p. 388-395.
 5. Lynn, Patricio B., Habr-Gama, Angelita, Perez, Rodrigo O., et al.: *Cylindrical abdominoperineal resection rationale, technique and controversies*. In: *Journal of Coloproctology* (2013); 33(3), p.167– 173.
 6. Mandache, F.: *Chirurgia rectului*. Bucureşti. Editura Medicala, 1971.
 7. Perry, Brian W., Connaughton, Cristopher J.: *Abdominoperineal Resection: How Is It Done and What Are the Results?* In: *Clin Colon Rectal Surg.* (2007); 20(3), p.213–220.
 8. Popescu, I.: *Tratat de chirurgie*”, Vol. IX, *Chirurgie Generală* (partea a II-a). Bucureşti. Editura Academiei Române, 2009.
 9. Pramatefakis, M.G., Raptis, D., Kanellos, D., et al.: *Abdominoperineal Resection for Rectal Cancer: Is the Pelvic Drain Externalization Site an Independent Risk Factor for Perineal Wound Healing?* In: *International Journal of Surgical Oncology*, Vol. 2012, Article ID 156935, 6 pages doi:10.1155/2012/156935
 10. Prişcu, Al.: *Chirurgie*, Vol. 2. Bucureşti. Editura Didactică şi Pedagogică, 1994.
 11. Rădulescu, D.: *Caiete de Chirurgie Practică 1*. Bucureşti. Editura medicală, 1982.
 12. Răzeşu, V.: *Chirurgie Generală. Vademecum pentru examene şi concursuri*. Piatra-Neamţ. Editura Răzeşu.
 13. Sinna, R., Alharbi, M., Assaf, N. et al.: *Management of the perineal wound after abdominoperineal resection*. In: *Journal of Visceral Surgery* (2013); 150, p. 9-18.
 14. Târcoveanu, E., Zanoschi, C.: *Amputaţia de rect*. In: *Jurnalul de Chirurgie*, Iaşi, 2006, vol II, nr. 2.
 15. Valadão, M., Cesar, D., Graziosi, G., et al.: *Operative Technique: Intersphincteric Resection*. In: *J Coloproctol* (2012); 32(4), p. 426-429.
 16. Wiatrek, R.L., Scott Thomas J., Papaconstantinou, H. T.: *Perineal Wound Complications after Abdominoperineal Resection*. In: *Colin Colon Rectal Surg.* (2008); 21(1), p. 76-85.