

POST-OPERATIVE RECOVERY OF LUMBAR DISC HERNIATION

Florentina NECHITA¹

Abstract: *Lumbar disc herniation is a common problem among people, especially those who are professionally active. The research emphasizes how to relieve lumbar pain, pain being the central symptom of disc herniation, and this can be solved by toning the hypotonic muscles. This will contribute to improving the functionality of the spine and even overcoming the patient's fear of movement after the operation. Thus, kinetic treatment methods and means will be applied in order to facilitate movements, reduce pain and reintegrate the patient into professional activity.*

Key words: *lumbar disc herniation; recovery; kinetic treatment; individualized recovery program.*

1. Introduction

It is determined by injuries that occur at the level of the intervertebral discs, which are spongy cylindrical structures located between the bony vertebrae with the role of absorbing shocks during walking, running or standing, as well as promoting the mobility of the spine [8].

The vertebral column is composed of a series of bones called vertebrae, linked together by an intervertebral disc, consisting of a fibrous and resistant outer ring and an elastic gelatinous tissue located in the center of the disc. A healthy intervertebral disc is like a shock absorber, which gives the spine protection against shocks produced by large movements, such as running, jumping or lifting weights. The weak point of the outer ring is directly under the root of the spinal

nerve and therefore the herniation in this area will cause a direct compression on the nerve.

If the discs are healthy, they have the role of absorbing shocks and keeping the spine flexible. When these discs are damaged by accidents or aging, they will protrude or rupture, a process called a herniated disc [10].

Lumbar disc herniations are common causes of lower back pain, neurological dysfunction, and buttock/leg pain.

Herniation refers to the displacement of the nucleus pulposus of the intervertebral disc through the annulus fibrosus, thereby causing pressure on the neural elements.

The sequelae of lumbar disc herniations range in severity from mild low back and buttock pain to severe cases of inability to ambulate and cauda equina syndrome [4].

¹ Department of Physical education and special motor skills, *Transilvania* University of Braşov, Romania

1.1. Anatomical-pathological classification

The impact on the body, induced by the herniated disc, is different depending on its location, size and type. In order to understand these phenomena, it is necessary to know some anatomical details.

From the point of view of appearance, the vertebra is similar in image to a lock. The main, massive part is called the "vertebral body", to which the "vertebral arch" is attached. The vertebral bodies are oriented anteriorly, towards the stomach, and the arches - posteriorly, towards the back. They also have some extensions, called spinous apophyses, which can be felt in the dorsal area of the body, fig. 1.

The intervertebral disc is located between the bony vertebrae and is smaller than them. The vertebral arches overlap each other forming a canal, which houses the spinal cord. Two nerve branches separate from the spinal cord, join to form the spinal nerve, surround the intervertebral disc, and exit the spine through a tunnel called the intervertebral opening (foramen), fig. 2.




Fig. 1. *Vertebra graphic representation* [6]

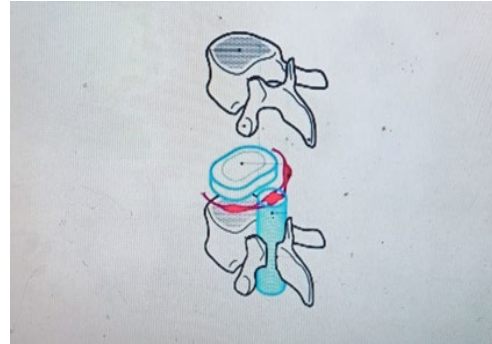


Fig. 2. *Intervertebral disc*, [6]

According to the criterion of the direction of movement, disc herniation is classified as follows:

- a. Anterior hernia - it is very rare, but if it occurs, it is stopped by the anterior common vertebral ligament, but it is installed below it. This displacement of the disc has no clinical expression, but in the future it may form a pathological bone change on the vertebral body.
- b. Lateral hernia - is represented by the lateral migration of the herniated disc material, it does not present symptoms at the level of the lumbar spine, unlike the cervical spine, where a lateral migration involves compression on the vertebral artery or on a root. cervical.
- c. Posterior hernia – is responsible for producing algo-functional symptomatology of the root compression type. We find several types of posterior disc herniation:
 - intraspinal hernias – the nuclear material goes towards the spinal canal, but this movement can be stopped by the posterior common longitudinal ligament and then it is a subligamentous hernia, but often the herniated material destroys the ligamentous barrier, the hernias becoming extraligamentous. And

those that break the posterior common longitudinal ligament can move reaching the vertebral canal.

- intraforaminal hernias – are hernias where part of the nucleus pulposus migrates towards the intravertebral foramen.
- extraforaminal hernias – are very rare cases, where the material of the nucleus pulposus moves towards the intervertebral conjugation hole and exceeds the external hole reaching under the muscles of the vertebral grooves.
- excluded hernias – are those in which the herniated nuclear material breaks from the rest of the nucleus pulposus, it can break in place or migrate cranially or caudally affecting another spinal root [5].

Stages of disc herniation:

Phase I-: disc instability phase: the initial phase in which dehydration and fragmentation of the nucleus pulposus occurs, at the level of the annulus fibrosus microcracks appear where cells from the nucleus pulposus migrate and from a clinical point of view the patient feels lumbar pain caused by inadequate positions, orthostatism or prolonged sitting, physical exertion that subsides after rest.

Phase II-: the migration of the nucleus: the cracks at the level of the fibrous ring are accentuated and migrate larger portions of the nucleus. From a clinical point of view, the patient feels acute lumbago with intense pain with limitation of the mobility of the lumbar spine and with irradiation along the path of the nerve root without going beyond the knee.

Phase III-: radicular form (externalized

disc herniation) with 3 stages:

Stage 1: irritative – in which pain radiates to the lower limb on a specific dermatome

Stage 2: neuritic – symptoms from stage 1 appear plus numbness, tingling and motor disturbances at the level of reflexes

Stage 3: paresis or paralysis - symptoms are lack of mobility with muscle weakness, pain, numbness and tingling, the patient has a limp or almost impossible walk with the affected limb.

Phase IV-: degenerative: in which spondylodiscarthrosis occurs, representing degeneration of the disc and arthrosis at the level of the vertebrae, the symptoms are similar to those listed above but are non-specific because several nerve roots are affected and the compressive phenomena are much more complex involving biomechanical disorders, degeneration disc and compressions caused by the inflammation of the surrounding tissues caused by arthrosis, myogelosis nodules, muscle contractions [9].

1.2. Clinical symptomatology of lumbar disc herniation

The main clinical symptoms of lumbar disc herniation in the acute stage are the following:

- a. Spinal syndrome - represents a group of objective and subjective clinical symptoms that appear at the beginning of the disease but also during it and includes the following symptoms: lumbar pain, static and dynamic disorders of the lumbar spine;
- b. Radicular syndrome - the variety of clinical forms can be correlated with the stage classification.

c. Dural syndrome - this syndrome is the result of the increase of cerebrospinal fluid in the medullary canal.

d. Myofascial syndrome - presents with pain in the buttock with or without other pain felt in the thigh, this syndrome is established long before the onset of lumbar disc herniation.

e. Psychic syndrome - the clinical manifestations of this syndrome are not very pronounced, and are rarely encountered. Some of them being skin color change, painful muscle cramps, cold extremities.

The presence of the first three syndromes is indispensable for drawing up a positive clinical picture, especially when the pain is acute, and the other two syndromes are not mandatory, but they may be present, it is possible that they may be complications of the underlying disease [5].

2. Paraclinical investigations and remedies

a. Radiological examination - it should be stated at the outset that a standard x-ray of the lumbar spine does not show an accurate sign of the existence of a herniated disc. Indirect signs are described in Barr's triad:

- the straightness of the lumbar spine;
- lumbar scoliosis;
- disk space compression.

b. Computed tomography – provides information on the diameter of the root canal and the condition of the soft tissues around the spine.

c. Electromyography – is a very useful investigation in radicular disc herniations, both for the stability of the affected parts and the regressive physiological changes it brings to the spine. This area shows which

muscle in the area is more affected.

The means of recovery are based on the following goals of physical therapy:

- General relaxation;
- Correcting body posture and alignment;
- Increasing joint mobility;
- Increasing muscle strength and endurance;
- Re-education of coordination and balance;
- Exercise training;
- Respiratory re-education;
- Re-education of sensitivity [2].

The fundamental means:

a. Kinetic exercise - it is structurally composed of three parts:

- Starting position and movements performed (A);
- The type of muscle contraction (concentric, eccentric, isometric) required during the exercise (T);
- Triggering elements of a sensory stimulus, with the aim of facilitating or inhibiting the response (E).

b. Massage - represents a methodical processing of the soft parts of the body, through manual or mechanical actions, for physiological or curative-prophylactic purposes. It consists in the manual, mechanical or electrical, methodical and systematic application of specific procedures on the soft parts of the body, for hygienic (physiological), prophylactic and therapeutic-recuperative purposes [3].

3. Material and Methods

The research subject is a male patient who underwent surgery to remove a large, ruptured, herniated L4 disc.

The case study was carried out at the subject's home and took place over a

period of approximately 3 months.

The recovery program used materials such as: elastic bands, dumbbells of different weights, sticks of different lengths, hoops, medicine balls, fixed ladder, rungs, massage table, gym mat, fitness balls, balance pad, kettlebell with different weight mass.

From those listed previously, in the recovery process the following were used: medicine ball, dumbbells with low weights, elastic bands, fixed ladder, kettlebell and massage table for performing exercises that must have a support point, but also for massaging to the patient when the muscles are tense on certain segments, for relaxation, pain relief, and muscle relaxation.

Evaluation tests of the research subject:
a. Joint balance of the dorso-lumbar spine;
b. Pain assessment, VAS scale.

3.1. Individualized recovery program

Recovery objectives:

- Prevention of postoperative complications;
- Combating pain and inflammation;
- Restoring the physical capacity of the spine and the peripheral neuro-muscular deficit, from the level of the lower limbs;
- Educating the patient on self-care techniques;
- Reintegration into family, professional, recreational activity;
- Prevention of relapses.

Recovery methods:

- Williams method – this method is used in the intermediate stage of kinetherapeutic treatment to increase the mobility of the lower trunk. Exercises for remobilizing the lumbar spine, tilting the pelvis, stretching the paravertebral

muscles and the psoas iliac are used.

It is divided into three phases:

- phase I and II for the subacute period: the pain in the decubitus has disappeared, the patient can move without pain.
- phase III for the chronic period, the patient can mobilize his spine, the pains are more moderate, so he is no longer forced to adopt a vicious position. [1].

- The McKenzie method – Theoretically, these movements, performed either from a vertical position or from a horizontal position, also help to improve the herniated disc, reducing the pressure on the nerve at the same time.

For the method to be effective, patients must avoid leaning forward, as this affects the strengthening movement. McKenzie exercises are also useful for people who have pain due to degenerative disc diseases [7].

Recovery program:

- a. Early recovery phase 0-6 weeks postoperatively:
 - postoperative posture in lateral decubitus;
 - lateral movements every 2 hours for the prevention of bedsores;
 - resuming the orthostatic position and walking with the sacro-lumbar segment blocked.
- b. Intermediate recovery phase:
 - improving the mobility of the lumbar spine;
 - pre-aggressive resumption of movements at the level of the sacro-lumbar segment.
- c. Late recovery phase:
 - professional rehabilitation.
 - re-entering normal activity.

4. Results and Discussions

The articular balance of the dorso-

lumbar spine was evaluated on the three tests: initial, intermediate and final, which identifies an active action and an effective approach.

The final data were obtained after a rigorous examination of the patient during the recovery program. The subject was subjected to spine-specific evaluations, to see exactly what the objectives of the physical therapy work are in this case, but

also for the good results at the end of the recovery. Due to the recovery period, a significant increase in flexion degrees is observed during testing, being constant and progressive from 5 to 5 degrees, from the initial to the intermediate testing, namely: from 60° to 65°. At the final testing the recorded value is 80°, an increase of 15°, being a normal value for this joint, table 1.

Evolution of joint balance

Table 1

	INITIAL	INTERMEDIATE	FINAL
Flexion	60	65	80
Extension	10	15	20
Laterality:			
Left	15	17	20
Right	10	15	20
Rotation			
Left	15	18°	30
Right	12	23	30

In figure 1 a considerable improvement of the flexion of the spine can be observed, starting from 70 degrees and reaching the specific parameters of 90 degrees. After the applied program, the increase was 20° in the final evaluation. This positive evolution is mainly due to the relevance of the intervention systems within the program.

The degree of spinal extension movement started at 10 degrees initially, and finally reached 20 degrees, with a progressive increase of 10°. These are the parameters specific to the extension of the spine.

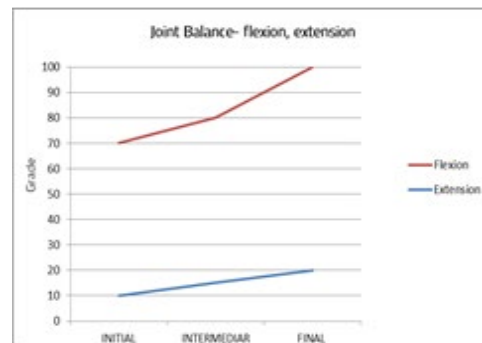


Fig. 1. *Joint balance of the dorso-lumbar spine*

Following the correct execution of the exercises and following the initially proposed objectives, the patient acquired better mobility in performing lateralizations. So, as can be seen, initially it started from 10 degrees on the right side, less than on the left side with a value of 15°, with an increase of 15° left and 17° right respectively, but towards the end

both movements have ended up falling within the normal parameters of 20 degrees, figure 2.

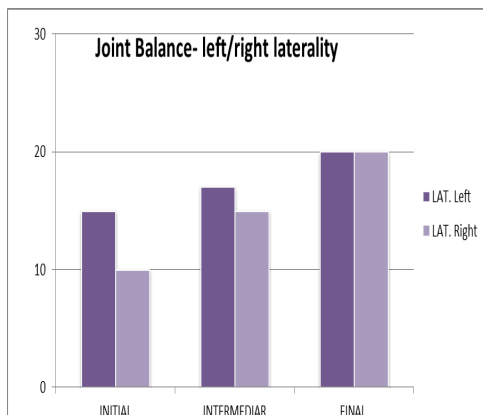


Fig. 2. Representation of joint balance left/right laterality

The left/right rotation movements of the trunk brought beneficial changes to the final evaluation, reaching the parameters of about 30 degrees, starting from 12° right and 15° respectively on the left side, fig.3. The intermediate evolution marked a significant increase of 3° to the right and 11° to the left, presenting values of 30° at the final testing for both directions of movement execution. Thus, this aspect also confirms the effectiveness of the applied recovery program.

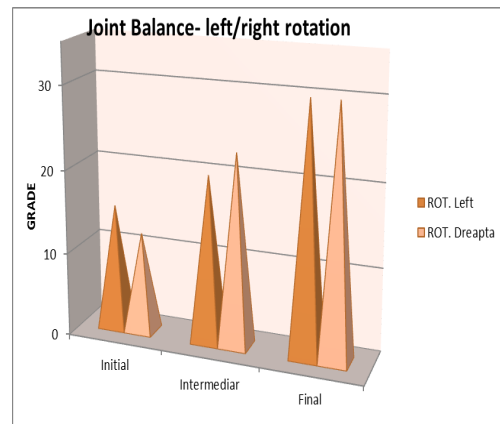


Fig. 3. Representation of joint balance left/right rotation

The VAS scale was used to assess pain, both at rest and during the recovery period. The value of the pain level recorded the value of 4, it decreased considerably to 2 at rest, and towards the end it was no longer present, table 2. The feeling of discomfort is a significant problem in any situation, having the ability to limit movement, the progress of recovery and the well-being of the individual. According to the visual analogue scale, the subject reported intense pain on movement, rated 6 in the initial test. Following the application of the program, the pain improved significantly, marking a value of 3 in the intermediate test, and finally, the subject reported no more painful sensations.

Pain evolution, VAS scale

Table 2

	INITIAL	INTERMEDIAR	FINAL
The level of pain in rest	4	2	0
Level of pain during activity	6	3	0

5. Conclusions

Considering the objectives proposed at

the beginning of the program and the results obtained during it, I claim that any patient regardless of age, sex, job can

recover in a very high percentage or even completely, returning to the daily activity provided, but with attention much more.

It is also very important to prepare the patient to deal with the situation in which he is, of temporary disability, to become the main factor of the treatment, so that the degree of independence and the manifestation of work capacity are maximally exploited.

References

1. Cristea, F.: *Metodologia recuperării kinetice a sindromului dureros lombar la persoanele de vârstă a II-a*. Chişinău, 2019, p.50.
2. Cotoman, R.: *Kinetoterapie – Metodica desăşurării activităţii practice*. Bucureşti, Editura Fundaţia România de Măine, 2006, p.9.
3. Mârza, D.D.: *Bazele generale ale kinetoterapiei*. Bacău, Editura Alma Mater, 2012, p.90.
4. Zhang, A., Xu, A., Ansari, K., Hardacker, K., Anderson, G., Alsoof, D., Daniels, A.H.: *Lumbar Disc Herniation: Diagnosis and Management*. The American Journal of Medicine, 2023, p.1, DOI: <https://doi.org/10.1016/j.amjmed.2023.03.024>.
5. ****Bourceanu, S.*, Available at: <https://balnear-corporesano.ro/doc-intern/4%20Protocoale%20medicale/PM-07%20HERNIA%20DE%20DISC.pdf> Accessed at: 21-07-2023.
6. *** *Petre, B.*, Available at: <https://www.petrebogdan.ro/hernia-de-disc-simptome-clasificare-cauze-diagnostic-tratament/> Accessed at: 11-09-2023.
7. ****Prokinetic*, Available at: <https://www.prokinetic.ro/terapia-mckenzie/> Accessed at: 22-09-2023.
8. ****ReginaMaria*, Available at: <https://www.reginamaria.ro/utile/dictionar-de-afectiuni/hernia-de-disc> Accessed at: 11-06-2023.
9. ****Restarti*, Available at: <https://www.restartix.com/hernia-de-disc-lombara/> Accessed at: 23-09-2023.
10. ****Stoicescu, H.*, Available at: <https://www.cdt-babes.ro/articole/hernie-de-disc.php> Accessed at: 22-09-2023.