

CORRECTION PHYSICAL DISABILITIES KYPHOSIS BY KINETIC MEANS OF A SPORTS PERFORMANCE

F. BENEDEK¹ E. RAȚĂ¹

Abstract: *This case study aims to determine the main directions in correcting physical deficiencies of the spine. There are numerous shortcomings of the axial skeleton, so I decided to study physical deficiency correction – kyphosis. Because this form of deficiency interest especially young people, adults, teens and children, we chose this topic for a thorough discussion, wanting to emphasize the important impact it has on the recovery program.*

This physical deficiency affects many people, from ordinary man with an incorrect attitude daily to athletes who acquire the deformation of practicing sport.

Physical therapy plays a very important role in correcting the deficiency, and through this therapy, serves primarily to correct the deformation of the spine, to create and maintain an attitude of body right, to increase and maintain muscle tone optimally to strengthens the respiratory muscles and promote harmonious physical development of the athlete in your experiment.

Key words: *athlete, disability, correction, kinetic means.*

1. Introduction

After a long period of uncertainty in recent years, development of knowledge and conceptions of physical therapy field has experienced a considerable acceleration and a remarkable development. Every aspect of the variety and complexity offered by elements musculoskeletal pathology was scrutinized by specialists in the field became almost completely known.

Some authors say that deficiency posture is deviation „from normal in shape and physical functions of the body that disrupt

the normal growth and harmonious development of body altering appearance, reducing the skills and power to adapt to physical strength, diminishing the ability of productive work”. [6] Physical functional deficiency to be presented in this study is kyphosis. This is a physical defect in the spine.

Author [5] argues in his „affections physiotherapy spine” published in 1984 by publisher Sport-Tourism that „kyphosis is an accentuation of the physiological curvature of the spine in the thoracic region. Kyphosis can count plummet when touching the tip of the dorsal curvature, is

¹ “Ștefan cel Mare” Suceava University.

to C7 spinous process of the vertebra, less than 3 cm distance”. [5] Otherwise defined, is kyphosis "a bowing of the spine in the sagittal plane with the convexity directed back due to vertebral structural morphological changes" in his vision [3].

According to the author Cordun M. kyphosis are “deviations of the spine in anterior plane with convex curvature far back. Typical kyphosis are common, are exaggerations of normal curvature in the dorsal region. Most typical are located kyphosis lumbar or cervical, where there are normally lordotic curves.” [4] Locating kyphosis is varied. The most common is the dorsal kyphosis, lordosis it is often associated with producing kypho-lordosis. Less common forms are total kyphosis (curvature in the lumbar vertebrae and ranging) and kyphosis low. The reverse curvature is rare.

Dorsal kyphosis is compensated by tilting upper neck and head before, and by emphasizing lower lumbar curvature. Kyphotic curvature has characteristics exhibited by length (short kyphosis, kyphosis long) and angulation (pronounced kyphosis or less pronounced). Kyphosis region corresponds to morphologic changes in the thorax morphological changes and positional ribs, scapula, shoulders, and these changes have a meaning in the form of skeletal muscle relief. Blades are spaced chest by stretching the trapezius muscle and rhomboidal and shortening the great pectoral. Clogged chest and shoulders carried forward. [2]

In kyphosis extension mobility is reduced to magnitude flexion, lateral bends, twisting themselves are reduced especially in the curvature kyphotic. Kyphosis are very common in school, especially during puberty and post-puberty, led by the work and in school, active processes of growth and physical

development and the lack of control on the attitude of the body.

Kyphosis multiple causes, some predisposing as: insufficient muscle, such as adolescents grew quickly in height, without muscle tone and ligament enough embarrassment girls reached puberty putting their breasts, resulting shoulders before kyphosis behind, wrong position in the desk or in the workplace, and myopia. Adult, ankyloses, spondylosis is one of the most common causes of cervical dorsal kyphosis progressive and irreducible. [1]

Kyphosis backbone retains its long normal mobility, which allows straightening curvature corrective exercises earnest. Kyphosis pathological treatment should be primarily etiologic and pathological, then symptomatic and functional.

Physical therapy plays a very important role in the recovery of deficiency. This therapy movement, serves primarily to correct the deformation of the spine, to create and maintain an attitude of body right, to increase and maintain muscle tone optimally to strengthen the respiratory muscles and promote harmonious physical development these children [7].

If wrong attitudes of children, especially during their stay in the bench, chair, physiotherapy aims to train sense of correct, by self continuously, which is possible given the flexibility of the spine, which can even hypercorrection with voluntary effort. It is envisaged improper position of the head fell onwards, to be redressed by muscle contraction neck with cervical curvature correction, keeping the gaze forward, parallel to the ground.

It aims at shortening conditions toning muscle groups in the back and toning abdominal muscles stretching conditions and chest. Of course, physical therapy has the role to correct or prevent deviations severance of the spine, or other segments.

2. Hypothesis

This case study follows a kinetic program effectiveness in water and on land for physical deficiency kyphosis correction to an athlete. It is assumed that the kinetic means can be corrected to a certain degree the natural deficiency kyphosis.

3. Scope

The aim is to systematize the most effective means for correcting kyphosis physical therapy while improving cardio-respiratory capacity, and the general condition of effort.

4. Objectives

With this work I wanted to achieve the following objectives:

- exposition of the most important aspects of deficiencies spine;
- providing the most effective guidelines for preventing and correcting kyphosis;
- explain how physical therapy work in programs;
- concrete organization of the work of regaining permanent evolution and incorporation of patient data;
- presentation of a material that comprises methods and means of correcting kyphosis and general programs for prevention of physical deficiencies in adolescents;
- implementation of results from research;

5. Materials and Methods

5.1. Study Organization

Venue and Basic Material Conditions

The first part of the research was carried out in a specialized physical therapy, equipped with apparatus necessary for the recovery program in the best conditions. Where I worked with recovery program and research was subsequently Swimming

Complex and Physical Therapy from the University of Suceava.

Cabinet in the complex is equipped with: Gym machines, banks, gymnasium, physiotherapy tables, Rocher cage, trellises, mobile correcting mirror, balance boards, Swiss balls, medicine balls, weights of different sizes, elastic bands, mattresses, pulleys, sticks, lamps and spirometry.

The subject was included in the research is the sport of volleyball team was in Suceava, and is currently a student at L.P.S. Suceava.

The patient R.A. He is 16 years old. A second study was carried out in the swimming pool is equipped with a mobile platform, which was carried out both in an exercise program shallow water and deep.

5.2. Doctor's Diagnosis

Dorsal Kyphosis Duration and Stages

The time in which conducted the recovery program was 4 Monday, September 2016- December 2016 in the office of physical therapy in the complex swimming. To assess the athlete were used the following tests: Test OTT, Stibor test, test separation fingers and test finger-ground distance.

Recuperation program consisted of passive mobilization exercises correcting posture and toning exercises for muscle growth and development exercise capacity were applied under aerobic exercises.

5.3. Postural Exercises

- a. Adopt and maintain the correct position before a mirror.
- b. From staying away, maintaining a level dorsal stick with outstretched arms.
- c. From supine, knees bent 90 degrees, feet resting on a wall with feet flat on it will perform tilting the pelvis back, setting the scapula.

- d. From supine, knees bent 90 degrees, feet resting on a wall with feet flat on it will be tilted pelvis and shoulder blades back fixing extension carrying arms in the head. It will place a towel or pillow under the curve dorsal anatomical
- e. Sitting on knees, back straight, arms point backwards, hands resting on his heels, carrying the pelvis forward slightly, keeping your head and neck in extension exaggerated, with blades close.

5.4. Walking Exercises

Exercises on the go:

1. From standing, arms point backwards, with folded hands, arms extension runs concurrently with every step the subject is making.
2. From standing, elbows grabbed from behind, walking with body extension every two steps.
3. Toe-walking, arms outstretched above the head with a baton in the extremities, trunk extension and running head at every step.
4. Walking with trunk bent 90 degrees, back straight, head in a slight extension, keep the medicine ball back region using head.
5. Toe-walking with hands behind your head, elbows side went back, torso arching runs at every step.

6. Dynamic Exercises for Kyphosis Correction

1. From prone, arms outstretched in the head extension, will run simultaneously raising his right arm with his left foot (arm opposite leg) alternating with left arm and right leg.
2. The patient sits on the abdomen Swiss ball, hands on trellis steps up to shoulder level, runs a leading arms

thrust in the chest as close to the trellis trunk finding himself in an exaggerated extension.

3. The patient sits with the ball Swiss on abdomen, legs resting on the top step of the trellis, arms bent, hands behind his head, runs an exaggerated extension of the trunk.
4. From the starting position on his knees slightly, move the Swiss ball forward until torso reaches parallel to the supporting surface. Hands will always be on the ball for balance. Returning to the starting position will be done by pulling the ball toward patient

6.1. Exercises in Shallow Water

1. From standing with one foot on a rung of the ladder, pelvis, hands behind his head half rotations of the trunk.
2. From standing with one foot on a rung of the ladder, pelvis, trunk extension with carrying arms to back;
3. From walking, hands behind his back, lifting his knees toward alternative water surface, keeping torso straight.
4. Toe-walking with rotating arms back.
5. Walking with a swimming raft on his head and carrying three steps as far back shares.

6.2. Exercises in Deep Water

1. Legs crawl with his hands resting on a raft, torso and head in slight extension.
2. Sliding back with arms outstretched in the extension of the body.
3. Sliding back with arms outstretched, 6-foot swimming beats with one arm (left, right).
4. Process rear (alternative arm) on certain distances.
5. Rear double (simultaneous arms) on certain distances.

7. Results and Discussions

After the program recovery kinetic following values were obtained, presented, in table number 1.

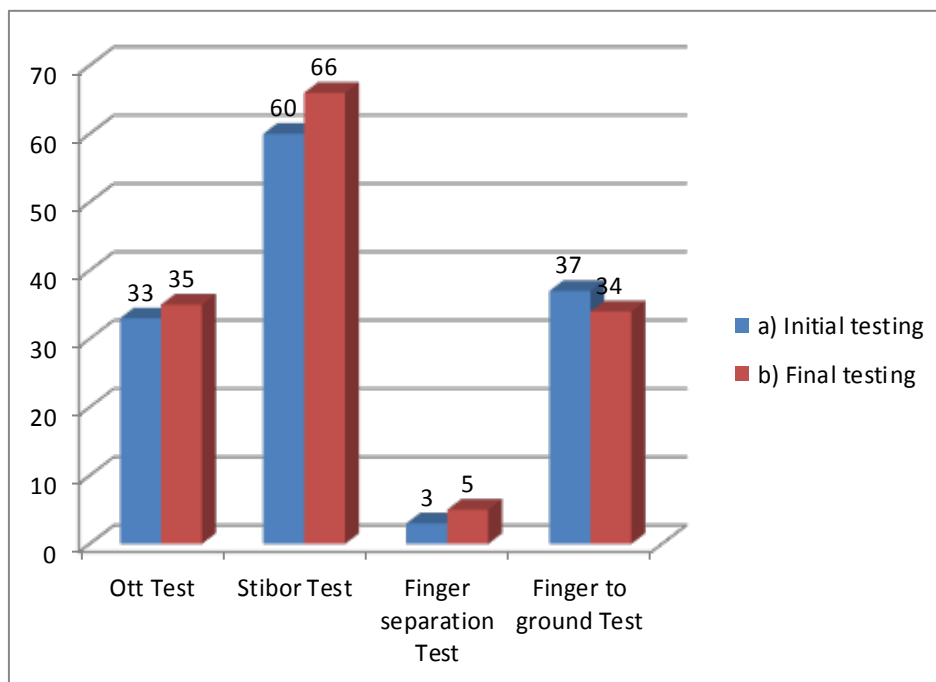
Comparative interpretation of data between initial and final test

Table 1

No. Crt.	Test Name	Initial Value	Final Value
1.	Ott Test	Ott = 30/33 cm	Ott = 30/35
2.	Stibor Test	Stibor = 55/60 cm	Stibor = 55/65 cm
3.	Fingers separation Test	Distance = 2 cm (standing), 3 cm (flexed)	Distance = 2 cm (standing), 5 cm (flexed)
4.	Fingers-to-Ground Test	Distance = 37 cm	Distance= 34 cm

After performing kinetic program, the subject has improved degrees of mobility of the spine, with progressive differences in all tests. In the following chart we

showed the results of initial testing, which can be seen on the graph columns blue, with final testing results marked in red.



Graph 1. *Representation of results from the initial test and final test*

We can observe patient progress, improve mobility and efficiency of exercises in the recovery program.

Ott test progress is visible 2cm. between initial and final testing, the test can be seen an improvement Stibor 6 cm.

The separation finger test progress is still 2 cm., and fingers away from test-ground progress has been 3cm.

8. Conclusions

Interpreting the results obtained have reached the following conclusions:

The hypothesis from which we started was checked;

- 1.Prevention underperformance is a priority work in preparing a program of physical therapy;
- 2.Applied early, recovery program may shorten patient recovery and its deficiency;
- 3.For greater efficiency, the patient should continue recovery program performed at home without the presence of physiotherapist;
- 4.Following the 4 months of rehabilitation the chest pain was completely reduced;
- 5.Following the final test, we realized that the program had multiple benefits of physical therapy because the patient has achieved a healthy human both parameters of motion and muscular

6.At the end of the rehabilitation program recommended increased attention on the posture in any daily activity.

References

1. Antonescu, D.: *Locomotor pathology*, Vol. I – II. Bucureşti. Editura Medicală, 2010.
2. Bălăceanu, A.: *Methodically practical guide on preventing and correcting the main attitudes and physical disabilities to school*. Suceava. Editura U.S.V., 1981.
3. Birtolon, Şt.: *Exercise and spine*. Bucureşti. Editura Sport-turism, 1978.
4. Cordun, M.: *Medical kinesiology*. Bucureşti. Editura Axa, 1999.
5. Dumitru, D.: *Physiotherapy affections spine*. Bucureşti. Editura Sport-turism, 1984.
6. Fozza, A.C.: *Guidance for correcting physical deficiencies*. Bucureşti. Editura Fundația România de mâine, 2002.
7. Manole, V.: *Physical therapy for diseases of sport performance*. Iaşi. Editura Pim, 2009.