

THE ROLE OF KINETOTHERAPY IN IMPROVEMENT OF KYPHOSIS TO ADOLESCENTS

Silviu Gabriel CIOROIU¹

Abstract: *The kyphosis among adolescents is a disease that affects both physically and mentally, because it is particular interest but especially to help patients, in terms of early diagnosis and health education. The vertebral column is the central segment of the human locomotor system, which, with vertical alignment, is of particular importance. Thus, it performs a number of functions, such as from a certain point of view, supporting the body in space, the strength to withstand the forces of gravity and to protect the spinal cord together with its nerve roots. In other respects, the spine must be sufficiently mobile to allow for flexion, extension, rotation, and inclination of both the head and the trunk. In conclusion, counseling sessions and intervention techniques had a positive effect on adolescents in the research*

Key words: *health, adolescents, exercise, kyphosis, massage.*

1. Introduction

The column should protect the noble nerve tissue without limiting mobility. This can only be possible due to a complex osteolygamental and muscular multisegmentation structure and a complicated physiology.

A complex of causes can stand in the way of this harmonious balance of the spine, preventing it from performing its functions. Appearing during childhood, these imbalances, either on the front or on the sagittal plane, may worsen during puberty growth until maturity. [1]

The vertebral column is located in the median plane, in the posterior region of

the trunk consisting of 33-34 vertebrae. Vertebrae connect the neck, the chest, the lumbar region and the pelvis. The vertebrae are arranged one above the other and divided by the regions to which they belong.

We delimitate four regions of the spine:

- a. The cervical region composed of seven vertebrae (C1-C7);
- b. The thoracic region composed of 12 vertebrates (T1-T12);
- c. The lumbar region composed of 5 vertebrae (L1-L5) - all of these regions beings made of independent bones (true vertebrae);
- d. The sacrococytine region composed of 9-10 vertebrae, of which five sacral

¹ Department of Physical Education and Special Motricity, *Transilvania* University of Braşov.

and 4-5 coccygiene, these being united forming two bones: the sacrum (S1-S5) and the coccyx (false vertebrae).

Incorrect body hold is more common during adolescence as a result of uneven development of the bone and muscular system. At the beginning of this period the long bones develop, with the muscles remaining behind.

With time, the muscles develop and the body takes the harmonious form of the adult (18-20 years). In order to avoid these column deformations and to fix the right outfit, it is good to be aware of their dangers, to seek to maintain our correct position and to stimulate the development of muscles through various physical exercises such as walks, games, moves in the open air, sports etc. - as well as a healthy diet (rich in protein).

Correction of these spine deformities is, of course, more difficult, through medical gymnastics, which provides a gradual return of the body to the normal position by strengthening the thoracic and back muscles [7].

2. Ethiopathy and systematisation

Vicious positions (in the bank, at work), myopia or spondylitis can favor cytotic attitudes. Another cause that can lead to the appearance of cytotic attitudes is the muscular insufficiency, often encountered in adolescents who grow rapidly without sufficient muscle and ligament tonus. Another cause is encountered in puberty girls they hide their breasts by leading shoulders [2].

Other causes may be:

- Congenital: vertebral body defect, familial vertebral malformations;
- -Neuro-muscular: neurological

disorders, medullary tumors;

- Post-traumatic (spinal cord injury due to accidents, fractures or contractions of tetanus or epilepsy);
- Spinal tumors;
- Genetic skeletal diseases;
- Post-inflammatory: Pott's disease (bone tuberculosis)
- Constitutional Asymmetry [5].

In terms of vertebral changes and curvature reductibility, there are categories of genotypes:

Functional or postural hematopoiesis, which are not accompanied by changes in the structure of the vertebral bodies and which can disappear from the decubitus position or by the astute prepubertal and pubertal asthenia, often encountered in children with a spontaneously reducing and decubitus reduction of thoracic chest. By ligament laxity and muscular hypotonia due to pregnancy and childbirth, there is the possibility of a functional enhancement of normal chest. In other circumstances, vicious attitudes are closely linked to pathological changes at a distance and disappear with correction. A good example would be myopia, which, uncorrected by glasses at the time it takes, can lead to a chest phagosis. If the presence of these deviations persists, over time it can lead to their structuring.

3. Criteria for supporting the diagnosis

3.1. Clinical picture

From a clinical point of view, in the case of cystoscopes, we cannot talk about a general rule regarding the symptoms of these vertebral deviations. Each type, therefore, has both subjective and different aims. There are however, several symptoms and objective signs that we encounter in several cases, namely:

- Dure, which occurs at the curve level. She feels at the palpation, but especially at the percussion;
- Spinal cord sprain accompanied always by the contraction of long back muscles and some stiffness in movements;
- Cytophobia is associated with the hypotonia of the muscles of the back and abdomen;
- Often associate with flat foot;
- Patients will have their fallen shoulders and shoulders "wings" [6].

3.2. Objective exam

Kyphosis deviation gives the whole body a global kyphosis attitude, characterized by a large spinal cord sprain and a bump of the entire back.

The head and neck tilt long before, the shoulders are brought forward, the chest is flattened the abdomen is sometimes sucked, sometimes bloated.

The basin is slightly inclined and the lower limbs are straight or slightly tangled from the knee joint. Depending on the curvature, the kyphosis deviations can be progressively accentuated, with an accentuated or highly accentuated curvature. They can only be confined to the spine elements, or they can affect other anatomical elements of the back, forming the chemo back. The most common kyphosis curves are of medium length, there are also short curves that are limited to a few vertebral bodies or long stretches of a large number of vertebrae.

Correct body attitude is a sign of the physical and mental balance of the individual, the result of normal and harmonious body development [6].

3.3. Treatment

The treatment is applied according to the type of the figure. The treatment of the orthopedist, the physical therapist, the functional explorer, the radiologist, the neurologist, the nutritionist, etc. must not be missed.

3.3.1. The objectives of the treatment

The treatment aims at achieving the following goals, namely:

- correct the vicious position;
- toning of paravertebral, abdominal and pectoral muscles;
- reproduction of vertebral mobility;
- breeding pain;
- preventing the recurrence of the genotype by various methods;

3.3.2. Treatment for kyphosis

It installs the sense of correct posture (self-contraction), an example of contraction would be, neuromuscular contraction. Consider the faulty head position by recovering with the muscle contraction of the neck and correcting the cervical curvature. The treatment is applied in the form of a static and dynamic exercise program. Static exercises: can be performed in the fanatic position but also the derivatives of this position. The trunk must be kept outdoors in the dorsal region. We need to pay attention to the lumbar region to prevent the occurrence of lordosis. The trunk is tilted forward or bent in the lumbar region. We fix the upper limbs to the shoulders and above their level.

Dynamic exercises (for shoulder proximity): they can be performed freely by external rotation of the arms, swinging in the median plane (approaching the shoulder blades), the ribs that are

attached to the spine can be trained and contribute to the thoracic spine clogged) by moving between them and lifting them.

Recommendations:

- sleep on the hard bed;
- the practice of certain sports that helps to correct the vicious position such as: swimming (back), skating etc-position control sitting on a back seat glued to the back [2].

4. Description of other means of physiotherapy

4.1. Thermotherapy

Thermotherapy is part of medical therapy that involves procedures that develop a large amount of heat. The main effects of thermotherapy are: hyperaemia, hyperthermia, muscle tone increase, increased elasticity of connective tissue. All these are favorable for training and recovery through physical therapy and massage.

Thermotherapy procedures:

- A general or partial steam bath is performed as follows: the patient is seated in a chair in a special closet, and cold compressions on both the forehead and the paracord are applied. The time of the bath is based on the disease and the desired result.
- The light baths take place in a special cylinder-shaped space, equipped with 40 60W bulbs and a thermometer. The temperature in that space is 60 ° -80 °.
- Sunbathing is done by exposure to the sun but the body must be protected from special oils. The procedure should be done 3 times a day.
- Sauna: The procedure takes place in a closed space where the temperature is between 80 ° -100 ° C. After the sauna, the

patient has to make a cold shower.

- Sludge hypertherm baths: sludge packing consists in sludge at a temperature of 47 ° C in a particular region. The procedure ends with a cooler shower (for cleaning, but also to bring the body temperature back to normal).
- Sludge muds are made in the seaside resorts by lubricating a body or body segment entirely with sludge. Eventually the patient will remove the sludge and relax in the shade. This procedure is a good medicine against colds.
- Paraffin wraps: apply paraffin from the tray to the affected area for 20 min.

4.2. Electrotherapy

Electrotherapy has some applications in the deformities of the column. It is used for curative and prophylactic purposes.

The galvanic current is obtained with the help of medical generators of direct current. The galvanic current can be produced by the following methods:

- a) Chemical methods;
- b) Mechanical methods;
- c) Thermoelectric methods;

"The physiological effects of galvanic current:

- Action on sensitive nerve fibers, the action being stronger at the anode.
- Action on motor nerve fibers. It produces stimulating effect-excitement occurs at the cathode and performs muscle contractions.
- Action on the central nervous system, descending application of galvanic-cranial (+) analgesic, distal (-), a stimulating effect was found.
- The action on the vegetative nervous system. In case of application in the cervical region, it has a non-specific neuro-vegetative regulation effect [3].

Ultrasound therapy is the therapy that occurs by applying sonic vibrations that exceed the excitatory threshold of the auditory for therapeutic purposes.

4.3. Massage

Massage treatment is a therapeutic procedure consisting of maneuvers performed on the body surface with a certain intensity and in a certain order, depending on the area to be massaged, on the evolution of the disease and on the general condition of the body for therapeutic, hygienic or sports purposes. Sedative action is achieved by mild, slow maneuvers that repeatedly stimulate existing exteroceptors and proprioceptors. Local hyperemic action is manifested by the warming and redness of the skin on which the massage is exercised; this action is achieved by more energetic maneuvers.

The most important physiological action of the massage is the reflex mechanism on the internal organs. This is explained by stimuli that go through exteroceptors and proprioceptors (stimuli that are of varying intensity) on a pathway to the CNS, and from there on the efferent path, they reach the inner organs in distress. Another mechanism of massage is the mechanical action produced by specific maneuvers which leads to muscular toning, improving muscle function and strength.

A recommendation to apply the massage for prophylactic and/or therapeutic purposes may only be made after a general clinical examination, followed by establishing the correct diagnosis of the disease. Thus, the physical therapist will know the particularities of the subject and will discuss the massage procedures he will use, as well as the methodology for their application. It will

also set the duration of a meeting, possibly rhythmically integrating it into the complex recovery program [4].

In the research, the massage sessions for the two patients diagnosed with cystosis helped them in the proportion of 5-30%. The massage sessions took place at the beginning of each kinetotherapy session after a clinical examination and the correct diagnosis of the disease.

For the case 1, the massage session lasted 20 minutes. In the first phase, the massage was applied to the entire surface of the back, which insisted on the areas: cervical and lumbar. After the massage session, the patient pauses for about 10-15 minutes during which he prepares the beginning of the kinetotherapy session.

For the patient in case 2, the same procedure was followed only for insisting on the thoracic and lumbar area.

Table 1
Percentage of the effect of massage on cases 1 and 2

Subject	Case 1	Case 2
Massage	35°	25°

The kinetherapeutic program [9] applied lasted 4 months and a half, and a kinetotherapy session lasted 45 minutes. There have been 18 sessions throughout 4 and half months.

Following the kinetotherapy program and the initiated massage, the patient, case 1, recovered 30-35%. Kyphosis at 25° was reduced after 4 months to 23° (Figure 1).

In the case 2 was recovered in the proportion of 32%. Between T5-T8 at 26° from the first radiography was reduced to 26° at the last X-ray, and between T10 and L2 at 29° was reduced to 25° (Figure 1).

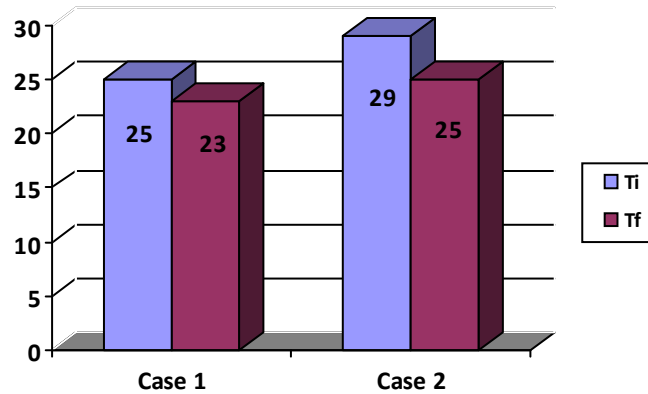


Fig. 1. Progress percentage from initial testing (Ti) to final testing (Tf), Case 1 and 2

4. Discussion

Following the analysis of the patients, the most appropriate treatment was to conduct physical therapy sessions, but also to practice a sport of choice [8].

Due to the counseling sessions, the transition from emotional state to those heavy moments has been achieved.

The values presented show that the recovery program was effective and the role of physical exercise and physical therapist in improving the cytochrome degree was demonstrated.

References

1. Antonescu, D.M.: *Pathology of the locomotor system*. Bucharest, Publishing house Medical, vol.2, 2018, 163-164, ISBN: 9789733906483;
2. Cioroiu, S.G. *Course notes - Recovery of physical deficiencies*. Brasov, 2011. 7-9.
3. Cioroiu, S.G. (2012). *Kinetherapy from theory to practice*, "Transilvania University" Publishing House, Brasov", 24-25, ISBN: 978-606-19-0061-9;
4. Cordun, M.: *Medical Kinetology*. Bucharest, "AXA" Publishing House, 1999, p. 268-272.
5. Heary, R.F. & Albert, T. J.: *Spinal Deformities. The Essentials*. New York, USA, Thieme, 2007, 22-34, ISBN-13: 978-1604064117.
6. Lenke, L.G., Kim, D.H., Betz, R.R., Huhn, S.L., Newton. P.O.: *Surgery of the Pediatric Spine*, 1st Edition, Thieme, New York, USA, 2008, 67-80, ISBN-13: 978-1588903426;
7. Mândruşca, E., Barnea, M., Peteanu, M. (1981). *Anatomy, physiology and human hygiene*. Bucharest, "Didactic and Pedagogical" Publishing House, 18-19.
8. Nechita, F.: Role of physical therapy in the treatment of obesity in age 9 -10. *Bulletin of the Transilvania University of Braşov*, Series IX, vol. 7 (56) No. 1, 2014, 41-46.
9. Nechita, F.: Effects corrective gymnastics physical education and sport lesson. *Bulletin of the Transilvania University of Braşov*, Series IX, vol. 9 (58) No. 2, 2016, 54-60.